

# Antithrombotic therapy for transcatheter structural heart intervention

Paul Guedeney<sup>1</sup>, MD, PhD; Josep Rodés-Cabau<sup>2</sup>, MD, PhD; Jurriën M. Ten Berg<sup>3,4</sup>, MD, PhD; Stephan Windecker<sup>5</sup>, MD; Dominick J. Angiolillo<sup>6</sup>, MD, PhD; Gilles Montalescot<sup>1\*</sup>, MD, PhD; Jean-Philippe Collet<sup>1</sup>, MD, PhD

*In memory of Professor Jean-Philippe Collet, a kind-hearted physician, a courageous interventional cardiologist, a brilliant researcher, a true mentor and a dear friend.*

\*Corresponding author: ACTION Group, Institut de Cardiologie, Centre Hospitalier Universitaire Pitié-Salpêtrière, 47 boulevard de l'Hôpital, 75013, Paris, France. E-mail: gilles.montalescot@aphp.fr

## ABSTRACT

Percutaneous transcatheter structural heart interventions have considerably expanded within the last two decades, improving clinical outcomes and quality of life versus guideline-directed medical therapy for patients frequently ineligible for surgical treatment. Transcatheter structural heart interventions comprise valve implantation or repair and also occlusions of the patent foramen ovale, atrial septal defects and left atrial appendage. These procedures expose structural devices to arterial or venous blood flow with various rheological conditions leading to potential thrombotic complications and embolisation. Furthermore, these procedures may concern comorbid patients at high risk of both ischaemic and bleeding complications. This state-of-the-art review provides a description of the device-related thrombotic risk associated with these transcatheter structural heart interventions and of the current evidence-based guidelines regarding antithrombotic treatments. Gaps in evidence for each of the studied transcatheter interventions and the main ongoing trials are also summarised.

Various transcatheter interventions have been developed in the last three decades for the treatment of structural heart diseases. They all involve exposure of cardiac devices to blood flow and, therefore, thrombosis formation during the early healing phase, justifying preventive antithrombotic treatments. Various antithrombotic treatments are available such as single (SAPT) or dual antiplatelet therapy (DAPT) and oral anticoagulation (OAC), prescribed individually or in combination. However, the optimal antithrombotic regime per type of transcatheter structural heart intervention has not yet been developed. In this state-of-the-art review, we aim to summarise the current evidence and provide perspectives on the evolving field of antithrombotic therapy as used following transcatheter interventions.

## Transcatheter aortic valve implantation TAVI IN PATIENTS WITHOUT AN INDICATION FOR CHRONIC ORAL ANTICOAGULATION

The optimal antithrombotic therapy post-transcatheter aortic valve implantation (TAVI) has been debated over the last

decade<sup>1,2</sup>. Most TAVI patients are older and/or frail and thus prone to both thromboembolic and bleeding complications. Based on the protocols used in the first landmark randomised controlled trials (RCTs) comparing TAVI to surgery, transient DAPT was recommended by expert consensus<sup>3</sup>. This assumption was eventually discarded according to consistent findings from both observational studies and RCTs with increasing sample sizes and statistical power<sup>4-8</sup>. In the cohort of the POPular TAVI trial, a total of 665 patients (mean age 81.0±5.9 years, 45.4% female, median Society of Thoracic Surgeons [STS] risk scores between 3.1 [interquartile range {IQR} 2.3-4.5] and 3.2 [IQR 2.2-4.8]) were randomised to receive either aspirin only or DAPT with aspirin and clopidogrel, with a loading dose the day prior to the procedure and continued for 3 months. Both primary endpoints, all bleeding and non-procedure-related bleeding over a 12-month period, were significantly reduced in the SAPT arm (risk ratio [RR] 0.57, 95% confidence interval [CI]: 0.42-0.77, and RR 0.61, 95% CI: 0.44-0.83, respectively). This gain in bleeding prevention was not offset by any significant increase in the

**KEYWORDS:** antithrombotic; patent foramen ovale; transcatheter; TAVI; transcatheter mitral valve implantation

rate of ischaemic complications, such as the non-hierarchical composite of cardiovascular (CV) death, ischaemic stroke, or myocardial infarction (MI), for which SAPT was demonstrated to be non-inferior to DAPT. Previous international guidelines by the European Society of Cardiology (ESC) and the American College of Cardiology/American Heart Association (ACC/AHA) proposed transient DAPT with class IIa and IIb recommendations, respectively<sup>9,10</sup>. Following the results of the POPular TAVI trial, the ESC updated its guidelines in 2021 to grant a class I, Level of Evidence A recommendation in favour of lifelong SAPT following TAVI in patients without any indication for chronic OAC<sup>11,12</sup> (**Central illustration**). Despite these findings, there are pending issues, as summarised in **Figure 1**.

#### SUBCLINICAL LEAFLET THROMBOSIS OF PERCUTANEOUS BIOPROSTHETIC AORTIC VALVES

Subclinical leaflet thrombosis (SLT) following TAVI has been the focus of intensive clinical research, especially with the increasing use of four-dimensional (4D) computed tomography (CT) scans, where it can manifest as hypoattenuated leaflet thickening (HALT) and/or reduced leaflet motion (RLM)<sup>13</sup>. In a recent meta-analysis, comprising 25 studies and 11,098 patients, the reported incidence of SLT was 6% overall and was significantly more frequent in case of an intra-annular valve (RR 2.03, 95% CI: 1.42-2.89) or treatment with SAPT or DAPT rather than OAC (RR 0.42, 95% CI: 0.29-0.61)<sup>14</sup>. SLT was associated with a significantly increased rate of the composite of stroke or transient ischaemic attack (TIA; RR 2.56, 95% CI: 1.60-4.09), consistent with previous meta-analyses, even when excluding periprocedural events<sup>14-17</sup>. The use of OAC following TAVI prevents or treats the occurrence of SLT, while the use of DAPT did not offer any improved protection compared to SAPT alone<sup>18,19</sup>. The optimal type and duration of OAC to be initiated after a diagnosis of SLT remains unclear. It should be noted that current guidelines recommend anticoagulation in patients presenting with both HALT and RLM, leading to an elevated gradient, at least until resolution<sup>12</sup>. Both vitamin K antagonists (VKAs) and direct oral anticoagulants (DOACs) may be initiated, and repeat 4D-CT valvular imaging should be performed, usually after a 3- to 6-month period<sup>20-22</sup>. Of note, SLT reoccurrence after OAC discontinuation has been reported, thus warranting prolonged monitoring<sup>23</sup>. This finding was part of the rationale behind the systematic use of a DOAC following TAVI in patients without any other indication for OAC, albeit unsuccessfully. The GALILEO trial, which compared a low dose of rivaroxaban (i.e., 10 mg q.d.) combined with 3 months of aspirin to 3-month DAPT followed by aspirin monotherapy, was prematurely


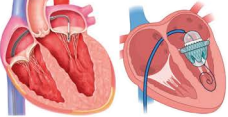


interrupted because of the significant increase in all-cause and non-CV death associated with the former (hazard ratio [HR] 1.69, 95% CI: 1.13-2.53 and HR 2.67, 95% CI: 1.33-5.35, respectively)<sup>24</sup>. This mortality increase was likely driven by a higher risk of Valve Academic Research Consortium (VARC)-defined major bleeding (HR 2.02, 95% CI: 1.09-3.76); of note, there was no significant gain in terms of ischaemic events, including ischaemic stroke (HR 1.28, 95% CI: 0.73-2.23). The ATLANTIS trial evaluated the use of apixaban compared to standard of care, which consisted of SAPT/DAPT in patients not requiring chronic OAC (stratum 2) and of VKA in patients with an indication for chronic OAC (stratum 1)<sup>25</sup>. Although the study reported apixaban to be non-inferior to standard of care for the primary endpoint – a composite of ischaemic and bleeding events – in the whole population, in stratum 2, it was also associated with a significant increase in the risk of all-cause and non-CV death (HR 1.86, 95% CI: 1.04-3.34 and HR 2.99, 95% CI: 1.07-8.35, respectively), albeit without a significant increase in the risk of bleeding in contrast to what was observed in the GALILEO trial. In dedicated imaging substudies of both the GALILEO and the ATLANTIS trials, the use of DOACs significantly reduced the risk of SLT, compared to an antiplatelet-based regimen, in patients without an indication for chronic OAC but failed to reduce the risk of clinical stroke (**Figure 2**)<sup>26,27</sup>. More recently, the ADAPT-TAVR trial randomised 229 patients to be treated with either edoxaban or 6-month DAPT following TAVI<sup>28</sup>. The primary endpoint, which was the incidence of SLT on a 4D-CT scan at 6 months, was only numerically reduced in the edoxaban group (9.8% vs 18.4%;  $p=0.076$ ). Consequently, the routine use of DOACs following TAVI in patients without an indication for OAC has a class III, Level of Evidence B recommendation in the latest European guidelines<sup>12</sup>. Of note, the risk of very late (i.e., >1 year after the procedure) clinically significant valve thrombosis according to the VARC-3 criteria affected 2.1% of the low-risk patients treated with TAVI in the PARTNER 3 Trial, a significantly increased risk compared to surgical aortic valve replacement (HR 8.72, 95% CI: 1.12-68.12)<sup>29</sup>. As TAVI indications are progressively expanded to younger and lower-risk populations, future studies assessing systematic DOACs, perhaps with lower dosage, compared to antiplatelet therapy could be of interest for the prevention of SLT. Furthermore, ongoing phase III RCTs are evaluating factor XIa inhibitors in patients with various indications, such as atrial fibrillation (AF) with embolic complication or in the setting of coronary artery disease (CAD)<sup>30</sup>. Future studies evaluating the use of factor XIa inhibitors to prevent SLT after TAVI would be of interest, but the results of studies for other indications must be awaited first.

#### Abbreviations

<b>CV</b>	cardiovascular
<b>DAPT</b>	dual antiplatelet therapy
<b>DRT</b>	device-related thrombosis
<b>OAC</b>	oral anticoagulation
<b>PCI</b>	percutaneous coronary intervention

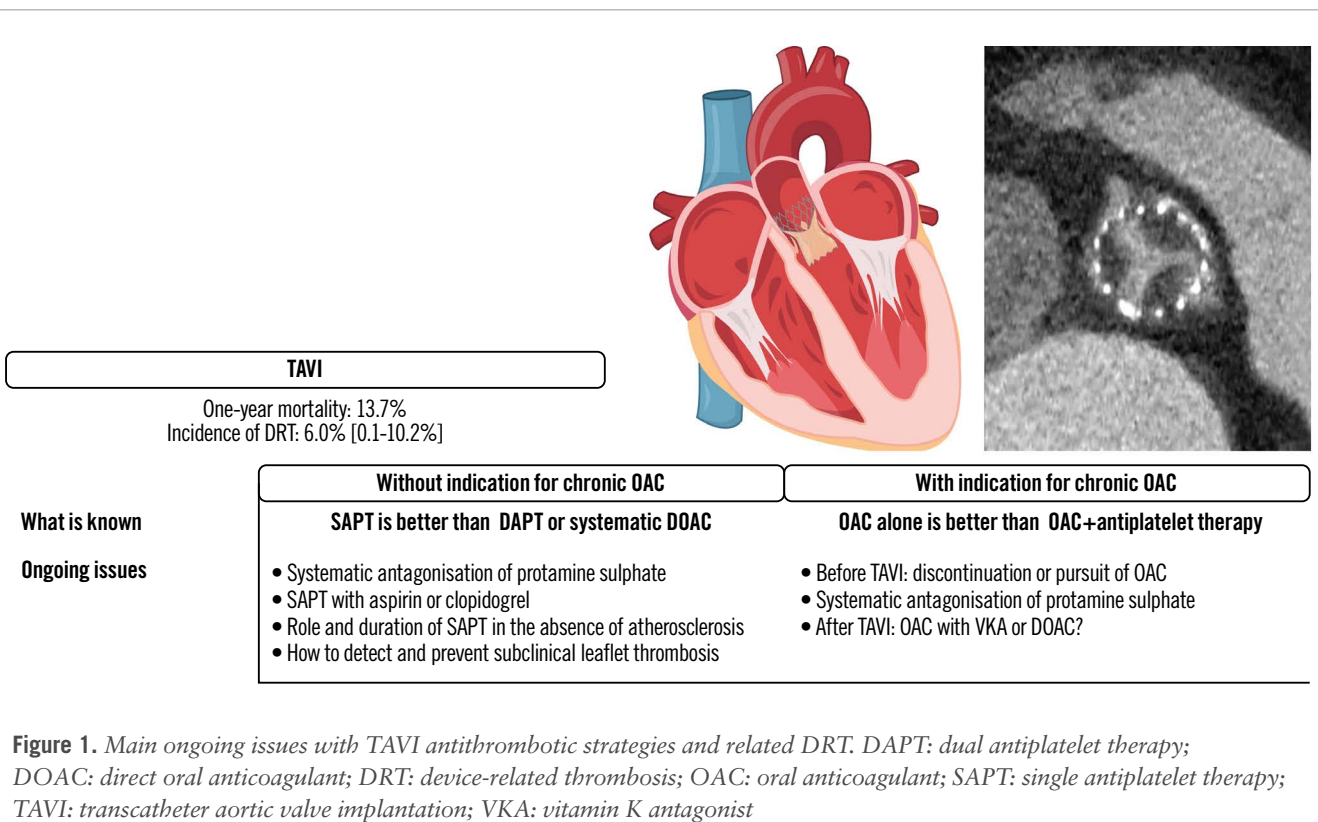
<b>RCT</b>	randomised controlled trial
<b>TAVI</b>	transcatheter aortic valve implantation
<b>TEER</b>	transcatheter edge-to-edge repair
<b>TMVI</b>	transcatheter mitral valve implantation
<b>VKA</b>	vitamin K antagonist

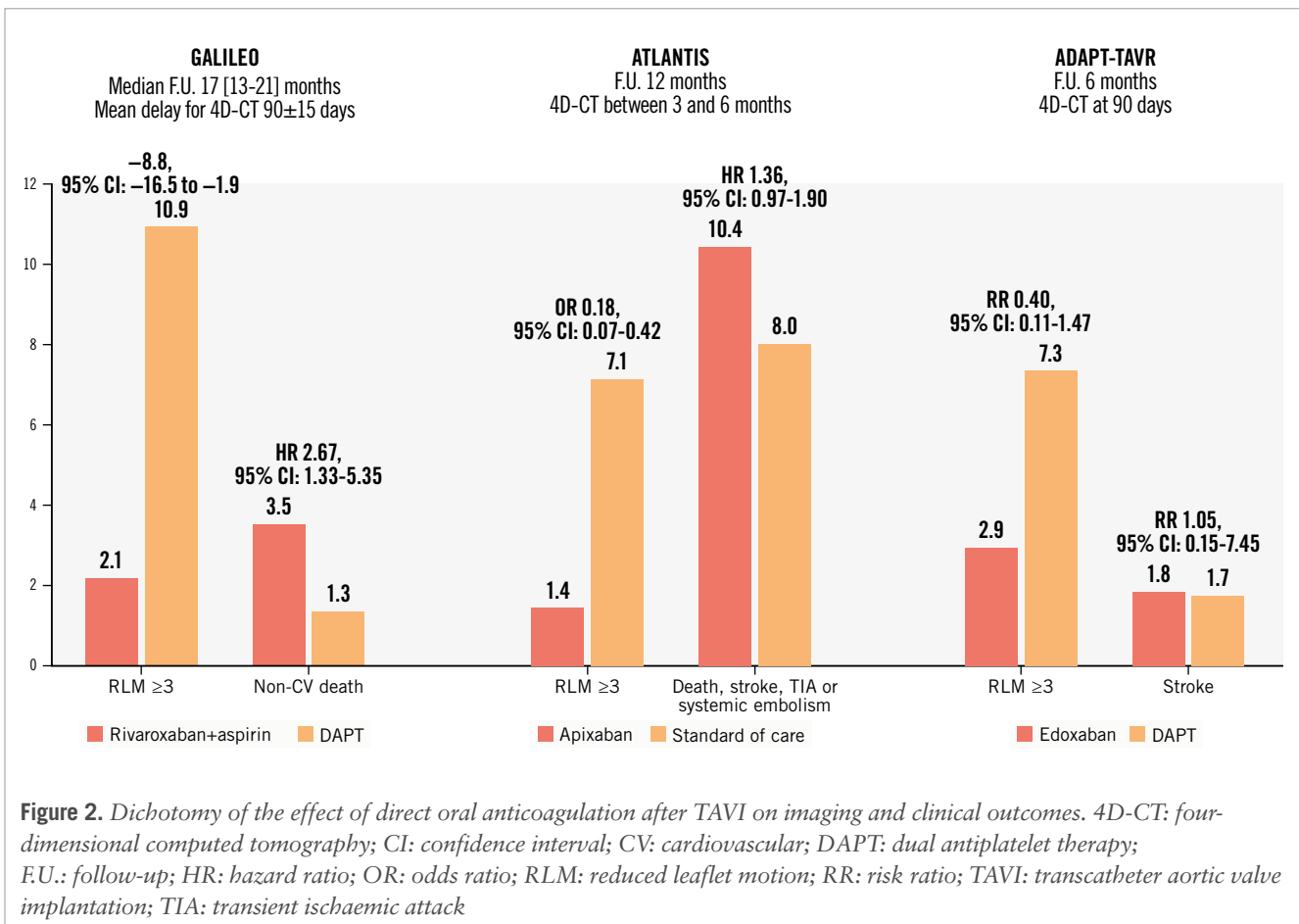
## Guidelines and expert-based consensus on antithrombotic therapy for transcatheter structural heart intervention.

Percutaneous procedures	Current consensus
<b>TAVI</b> 	<ul style="list-style-type: none"> <li>• Without indication for chronic OAC: lifelong SAPT</li> <li>• With indication for chronic OAC: OAC alone in the absence of a recent coronary event</li> </ul>
<b>Mitral or tricuspid</b> 	<ul style="list-style-type: none"> <li>• No evidence-based specific recommendations for antithrombotic therapy</li> </ul>
<b>PFO/ASD</b> 	<ul style="list-style-type: none"> <li>• Transient (1 to 6 months) DAPT followed by long-term SAPT</li> </ul>
<b>LAAO</b> 	<ul style="list-style-type: none"> <li>• If OAC is possible: VKA+aspirin (45 days) then DAPT until 6 months (if no leak) then long-term SAPT</li> <li>• If OAC is not possible: transient DAPT (1 to 6 months) followed by long-term SAPT</li> </ul>

Paul Guedeney *et al.* • *EuroIntervention* 2024;20:972-986 • DOI: 10.4244/EIJ-D-23-01084

ASD: atrial septal defect; DAPT: dual antiplatelet therapy; LAAO: left atrial appendage occlusion; OAC: oral anticoagulant; PFO: patent foramen ovale; SAPT: single antiplatelet therapy; TAVI: transcatheter aortic valve implantation; VKA: vitamin K antagonist





### WHICH ANTIPLATELET TO KEEP?

Lifelong SAPT following TAVI is recommended in patients without an indication for chronic OAC. SAPT is overwhelmingly represented by low-dose aspirin, as it is for percutaneous coronary intervention. So far, in the setting of TAVI, only 1 observational study from the Japanese OCEAN-TAVI registry has compared clopidogrel to aspirin in patients with and without an indication for chronic OAC<sup>31</sup>. After propensity matching, the median age was 85 years, the majority of patients were female, and the mean STS score was 5.8% in patients without anticoagulation and 7.5% in patients with anticoagulation. In the former group, the use of clopidogrel was associated with a reduction of CV death at 2 years (HR 0.81, 95% CI: 0.25-2.65), albeit without any significant difference in the risk of stroke or life-threatening or major bleeding, which most frequently occurred within 30 days of the procedure. Other observational studies comparing SAPT with clopidogrel versus aspirin following TAVI in other non-Asian populations are certainly warranted to confirm these results.

The REAC-TAVI trial demonstrated that DAPT with aspirin and ticagrelor led to improved antiplatelet activity compared to aspirin and clopidogrel, which was frequently associated with residual high platelet reactivity<sup>32</sup>.

### NO ANTITHROMBOTIC TREATMENT

Another observational study from the OCEAN-TAVI registry evaluated patients discharged without any antithrombotic therapy following TAVI<sup>33</sup>. Out of 3,575 patients discharged

without OAC or procedural complication, 293 (8.2%) were discharged without antiplatelet therapy per the attending physician's decision. As it could have been expected, the main motivation behind this antithrombotic abstinence was the perceived risk of bleeding of these patients, who were nonetheless younger and with less frequent chronic kidney disease or anaemia than patients discharged with antiplatelet therapy. After 3 years of follow-up, the adjusted risk of all bleeding was significantly reduced in the absence of any antiplatelet therapy compared with DAPT (HR 0.51, 95% CI: 0.27-0.95) and numerically reduced compared to SAPT (HR 0.63, 95% CI: 0.33-1.19), without any significant difference in terms of mortality or ischaemic complications. Based on these results, the Non-antithrombotic Therapy After Transcatheter Aortic Valve Implantation Trial (ClinicalTrials.gov: NCT06007222) was initiated in 2023 to compare aspirin-only to no antithrombotic therapy in 360 patients undergoing transfemoral TAVI. The primary endpoint is a composite of death, MI, stroke and bleeding (type 1 to 4) according to the VARC-3 criteria between 1 and 3 years of follow-up. Further studies confirming these results in other populations are warranted<sup>34</sup>.

### WHAT IS NEXT?

Two ongoing trials are comparing the impact of SAPT with aspirin versus antiplatelet P2Y<sub>12</sub> inhibitors on imaging and clinical outcomes. The ACLO-TAVR Trial was initiated in 2023 in Korea (ClinicalTrials.gov: NCT05493657) and will

include 230 patients initially treated with 1-month DAPT followed by either aspirin or clopidogrel only, and the primary endpoint is the incidence of SLT on cardiac CT at 3 months. The REAC-TAVI2 trial (ClinicalTrials.gov: NCT05283356) is randomising 1,206 patients with diabetes mellitus and prior documented coronary or peripheral artery disease to be treated, after a successful TAVI, with SAPT with either low-dose aspirin alone or ticagrelor 60 mg b.i.d. alone. The primary endpoint is a composite of death, stroke, transient ischaemic attack, MI, progressive angina leading to emergency evaluation, rehospitalisation or new coronary angiography, valve thrombosis, claudication, acute limb ischaemia leading to hospitalisation, or any bleeding. On the other hand, a third, recently initiated, trial is evaluating the interest of an antithrombotic strategy based on the results of systematic 4D-CT scan evaluation and the clinical characteristics of the patients. The POP ATLANTIS (ClinicalTrials.gov: NCT06168370) international, multicentre, event-driven, open-label trial will include 2,496 patients after a successful TAVI procedure. Patients are henceforth treated with aspirin for 3 months, after which they are randomised to either standard of care or an antithrombotic strategy, based on the results of a 4D-CT scan. In the absence of subclinical leaflet thrombosis, patients will be treated with SAPT or no antithrombotic therapy, in the presence or absence of vascular disease, respectively. In case of SLT, patients will be switched to apixaban with another 4D-CT scan evaluation after 6 months, at which point apixaban will be interrupted or continued according to the regression or persistence of the bioprosthesis thrombosis, respectively. The co-primary endpoints will be the composite of thromboembolic and all bleeding events.

#### TAVI IN PATIENTS WITH AN INDICATION FOR CHRONIC ORAL ANTICOAGULATION

Patients requiring chronic treatment with OAC currently represent approximately 40% and 16% of high-risk and low-risk patients undergoing TAVI, respectively<sup>1,35</sup>. The issue of concomitant prescription of antiplatelet therapy in this population was addressed by cohort B of the POPular-TAVI trial, which reported the addition of clopidogrel to OAC to be associated with a significantly increased risk of all bleeding (RR 0.63, 95% CI: 0.43-0.90) and non-procedure-related bleeding (RR 0.64, 95% CI: 0.44-0.92)<sup>36</sup>. Notwithstanding, some major issues remain.

#### TO CONTINUE OR TO STOP ORAL ANTICOAGULATION PRIOR TO TAVI?

Current expert-based guidelines advise the interruption of OAC in patients at high risk of bleeding undergoing interventions but do not address the specific issue of patients undergoing transfemoral TAVI<sup>37</sup>. Other expert-based consensus recommend the use of unfractionated heparin (UFH) sulphate aiming for an activated clotting time (ACT) >250-300 sec for periprocedural anticoagulation<sup>38</sup>. However, some observational data have reported the continuation of OAC to be safe and potentially associated with a reduction of the VARC-2 safety criteria<sup>39</sup>. The ongoing POPular PAUSE TAVI will be the first RCT to compare the continuation versus discontinuation of OAC, stratified on the use of VKA or

DOAC and on the incidence of CV death, stroke, MI, major vascular complication and type 2-4 bleeding, as defined by the VARC-3 criteria, within 30 days of the TAVI procedure<sup>40</sup>.

#### WHICH ORAL ANTICOAGULANT TO USE AFTER TAVI?

The use of a DOAC following TAVI, mostly to prevent AF-related thromboembolic complications, has increased 5.5-fold between 2013 and 2018 in the STS/ACC Transcatheter Valve Therapy (TVT) Registry<sup>41</sup>. The main observational studies comparing DOAC to VKA after TAVI are detailed in **Table 1**. Overall, the use of a DOAC seems to be safe, potentially reducing bleeding and ischaemic complications, albeit with some conflicting data. So far, only 2 RCTs have compared a DOAC to VKA. Stratum 1 of the ATLANTIS trial did not report significant differences between apixaban and VKA regarding either ischaemic or bleeding complications<sup>25</sup>. The ENVISAGE-TAVI AF trial randomised 1,426 patients following successful TAVI to treatment with edoxaban or VKA. Although edoxaban was non-inferior to VKA for the primary endpoint – a composite of death, MI, stroke, systemic thromboembolism, valve thrombosis, or major bleeding (HR 1.05, 95% CI: 0.85-1.31) – it was associated with a higher risk of major bleeding (HR 1.40, 95% CI: 1.03-1.91)<sup>42</sup>, mainly accounted for by the concomitant use of SAPT and DAPT in 57.8% and 12.6% of the population, respectively, and the frailty of the population, which met the criteria for a reduced dose of edoxaban in 46.4% of the cases. Notwithstanding these results, and while waiting for updated recommendations by international guidelines, the use of DOAC, with a dosage adapted to the patients' frailty and without systematic use of concomitant antiplatelets, seems reasonable in patients following TAVI.

#### PLACE OF CONCOMITANT PERCUTANEOUS LEFT ATRIAL APPENDAGE OCCLUSION

The WATCH-TAVR trial recently compared TAVI with concomitant percutaneous left atrial appendage occlusion (LAAO) to TAVI+medical therapy in 349 patients (mean age 81.1±7.2 years, mean CHA<sub>2</sub>DS<sub>2</sub>-VASc and HAS-BLED scores 4.9±1.2 and 3.0±1.1, respectively) with AF<sup>43</sup>. The combined procedures were non-inferior to TAVI+medical therapy for the composite primary endpoint of mortality, stroke and major bleeding at 2 years (HR 0.86, 95% CI: 0.60-1.22; p-value for non-inferiority<0.001) but were not superior (p-value for superiority=0.40) and were associated with an increased risk of arterial or venous thrombosis or embolism (HR 5.03, 95% CI: 1.47-17.26), mainly driven by venous thrombosis.

#### PERIPROCEDURAL CONSIDERATIONS FOR TAVI

Expert-based guidelines acknowledge the possibility of heparin antagonisation using protamine sulphate in case of a transapical approach and in case of major bleeding or vascular complications following a transfemoral approach<sup>38</sup>. One large retrospective study including 873 patients from 2013 to 2018 reported systematic use of protamine sulphate to be associated with a significant reduction in the risk of death, life-threatening or major bleeding complications (odds ratio [OR] 0.24, 95% CI: 0.10-0.58), as well as a shorter length of hospital stay, without any significant ischaemic offset<sup>44</sup>. These results were confirmed by a recent multicentre

**Table 1. Main observational studies comparing DOAC to VKA after TAVI.**

Registry or first author and year of publication	Years of recruitment	Location	Number of patients included	Means of comparison	Main results concerning the use of DOAC versus VKA
SwissTAVI, 2024 <sup>90</sup>	2007-2021	Switzerland	Overall: 3,867 VKA: 1,536 DOAC: 2,304	Propensity score matching	Increased risk of 5-year mortality (HR 1.25, 95% CI: 1.11-1.40) and lower risk of non-procedure-related disabling stroke (HR 0.64, 95% CI: 0.46-0.90) with VKA
GARY, 2023 <sup>91</sup>	2011-2019	Germany	Overall: 16,974 VKA: 11,333 (66.8%) DOAC: 5,641 (33.2%)	Propensity score matching	No significant differences in the risk of 1-year death (HR 0.95, 95% CI: 0.88-1.01) or cardiac and cerebrovascular event (HR 0.93, 95% CI: 0.86-1.01)
STS/ACC TVT, 2022 <sup>41</sup>	2013-2018	USA	Overall: 21,131 VKA: 13,004 (61.5%) DOAC: 8,127 (38.5%)	Adjusted Cox proportional hazard model	Reduced risk of 1-year all bleeding (HR 0.81, 95% CI: 0.75-0.89), intracranial haemorrhage (HR 0.54, 95% CI: 0.33-0.87) and death (HR 0.92, 95% CI: 0.85-1.00) with DOAC
Butt et al, 2021 <sup>92</sup>	2012-2017	Denmark	Overall: 735 VKA: 516 (70.2%) DOAC: 219 (29.8%)	Adjusted Cox proportional hazard model	No significant differences in the 3-year risk of arterial thromboembolism (HR 1.23, 95% CI: 0.58-2.59), bleeding (HR 1.14, 95% CI: 0.63-2.06) or death (HR 0.93, 95% CI: 0.61-1.40)
FRANCE-TAVI and FRANCE 2, 2021 <sup>93</sup>	2010-2017	France	Overall: 24,581 VKA: 15,619 (63.5%) DOAC: 8,962 (36.5%)	Propensity score matching	Reduced risk of 3-year death (HR 0.73, 95% CI: 0.60-0.89) and major bleeding including intracranial haemorrhage (HR 0.61, 95% CI: 0.44-0.85) with DOAC
OCEAN-TAVI, 2020 <sup>94</sup>	2013-2017	Japan	Overall: 403 VKA: 176 (43.7%) DOAC: 227 (56.3%)	Propensity score matching (IPTW) and adjusted Cox proportional hazard model	After a median follow-up of 568 days, significant reduction in the risk of death (IPTW-adjusted HR 0.53, 95% CI: 0.29-0.96 and Cox-adjusted HR 0.39, 95% CI: 0.20-0.75) with DOAC
Jochheim et al, 2019 <sup>95</sup>	2007-2017	4 centres in Germany and Italy	Overall: 962 VKA: 636 (66.1%) DOAC: 326 (33.9%)	Propensity score matching (IPTW)	Increase in the risk of 1-year death, MI or cerebrovascular event (adjusted HR 1.44, 95% CI: 1.00-2.07) with DOAC

CI: confidence interval; DOAC: direct oral anticoagulant; HR: hazard ratio; IPTW: inverse probability of treatment weighting; MI: myocardial infarction; STS/ACC TVT: Society of Thoracic Surgeons/American College of Cardiology Transcatheter Valve Therapy; TAVI: transcatheter aortic valve implantation; VKA: vitamin K antagonist

observational registry where full heparin antagonisation resulted in significantly lower rates of life-threatening and major bleeding after TAVI compared with partial heparin reversal<sup>45</sup>. However, in a single-centre RCT with a limited sample size of 100 patients, systematic antagonisation of protamine sulphate failed to reduce the rate of major and life-threatening bleeding within 48 hours of the procedure (OR 0.48, 95% CI: 0.2-1.2)<sup>46</sup>. The POPular ACE TAVI (ClinicalTrials.gov: NCT05774691) was recently initiated and will include 1,000 patients undergoing transfemoral TAVI to be treated with routine or selective (i.e., in case of life-threatening bleeding) protamine administration (ratio of 1 mg per 100 IU of UFH). The primary outcomes are the composite of cardiovascular death or type 1 to 4 bleeding, according to the VARC-3 criteria. Consistently, the ATLANTIS PROTAMINE trial (ClinicalTrials.gov: NCT06215378) will randomise 940 patients undergoing transfemoral TAVI in France to be treated with systematic protamine administration versus selected protamine administration limited to cases of significant bleeding complication. The primary endpoint will include the composite of VARC-3 defined all-cause mortality, type 2, 3 or 4 bleeding, major or minor vascular complications, stroke or TIA, myocardial infarction or any red blood transfusion.

#### ANTITHROMBOTIC THERAPY AFTER PERCUTANEOUS MITRAL AND TRICUSPID INTERVENTIONS

Transcatheter mitral valve implantation (TMVI) is considered a high-risk situation for device-related thrombosis (DRT) due to the transmitral low-flow state and patient-related risk factors such as advanced age, concomitant AF, altered ventricular function or hypercoagulable state<sup>47</sup>. A relatively large single-centre registry of 130 patients undergoing TMVI with the SAPIEN device (Edwards Lifesciences) reported a 1-year cumulative rate of transcatheter heart valve thrombosis of 11.1% (95% CI: 6.5-18.2%), occurring mostly during the index hospitalisation or within the first 3 months post-procedure, despite an antithrombotic regimen of VKA, with a target international normalised ratio (INR) of 2-3, and low-dose aspirin<sup>48</sup>. Risk factors for device thrombosis were the presence of in-hospital haemodynamic shock due to acute thrombosis, male sex and the lack of early preventive OAC (i.e., within 3 months). Another observational registry evaluating the Tendyne prosthesis (Abbott) reported an incidence of device thrombosis of 6% at 1 year. It should be noted that the postoperative antithrombotic protocol was modified during the study course, with a switch from low-dose aspirin to the systematic use of VKA with a target INR of 2.5 to 3.5 for  $\geq 3$  months. Valve thrombosis may also be

a concern in case of valve-in-valve TMVI. A recent, relatively large single-centre registry reported DRT incidence at 2.5%, 5.9% and 8.4% at 1 month, 1 year and beyond 1 year, respectively, supporting the use of OAC after valve-in-valve TMVI<sup>49</sup>.

Mitral transcatheter edge-to-edge repair (TEER) is a more common intervention, compared to TVMI. In the landmark COAPT Trial, comparing TEER with the MitraClip device (Abbott) to guideline-directed medical therapy for the treatment of symptomatic severe secondary mitral regurgitation, the protocol mandated discontinuation of chronic OAC  $\geq 3$  days prior to the procedure, periprocedural UFH with a target ACT  $>250$  seconds and a loading dose of clopidogrel before or immediately after the procedure<sup>50</sup>. OAC was resumed when needed, or low-dose aspirin was to be initiated for 6 months. Although the trial did not adjudicate device thrombosis as safety endpoints, there were 2 (0.7%) centre-reported cases of “thrombosis in device” during the 5-year follow-up in the experimental group (**Figure 3**). Consistently, only a limited number of case reports about TEER DRT have been reported so far, mostly occurring during the index procedure rather than afterwards<sup>51</sup>.

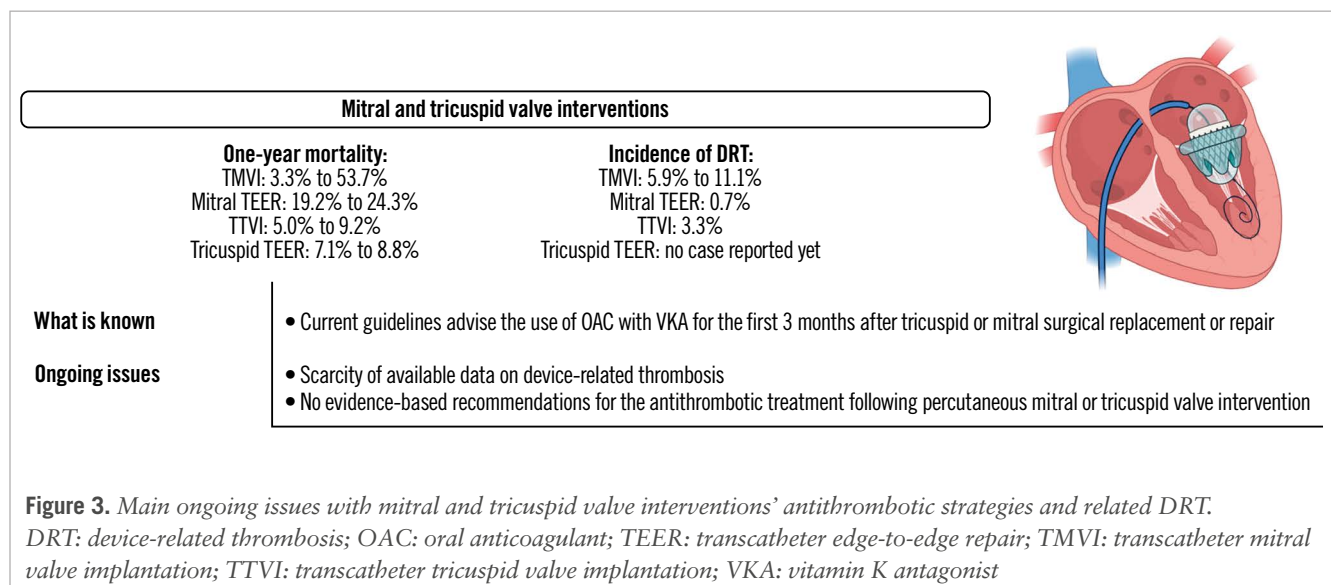
Tricuspid TEER was recently demonstrated to be safe and effective versus optimal medical therapy<sup>52</sup>. The protocol mandated resuming OAC after the procedure when indicated, i.e., in at least 90% of the overall population, or the use of aspirin with or without clopidogrel for at least 6 months. No case of DRT was adjudicated by the central core lab of the study within 30 days of the procedure. Consistently, the large real-world bRIGHT post-approval study of 511 patients undergoing TEER with the TriClip (Abbott) did not report any DRT<sup>53</sup>.

Large RCTs evaluating transcatheter tricuspid valve implantation (TTVI) are ongoing. The large observational VIVID registry reported outcomes following TTVI, with either the Melody (Medtronic) or SAPIEN valve, in patients with a prior tricuspid prosthesis or ring<sup>54</sup>. Of the 306 patients included, a total of 8 presented with device thrombosis over the median 15.9 months of follow-up, of which 3 occurred within several days of the procedure, 2 within months and

3 after 6 months of the procedure. Most of the cases occurred in patients not treated with OAC at the time of diagnosis. The recent, prospective, international TRISCEND Study reported outcomes following TTVI with the EVOQUE (Edwards Lifesciences) device in patients with  $\geq$ moderate symptomatic tricuspid regurgitation<sup>55</sup>. There was no reported case of device-related pulmonary embolism, although the specific rate of DRT was not detailed in a population of patients overwhelmingly treated with OAC.

### SCARCITY OF DATA ON DEVICE-RELATED THROMBOSIS AND POSTPROCEDURAL ANTITHROMBOTIC TREATMENT

Data on DRT are scarce, leading to significant differences in real-world practices after these interventions, which are aimed at different patient populations, with significant variations in term of rheological conditions and thrombotic risk<sup>56</sup>. The rate of DRT seems to be significantly higher in case of percutaneous mitral or tricuspid replacement rather than repair, although prothrombotic comorbidities, such as older age, AF, and altered ventricular function, are quite common in both situations. Current international guidelines recommend the use of VKA for the first 3 months after tricuspid or mitral surgical repair or bioprosthesis implantation and continuation of DOACs rather than VKAs when needed. The indication for long-term OAC may be significantly more frequent for these procedures compared to TAVI, with more than half of the COAPT population and 90% of the TRILUMINATE patients presenting with a history of AF<sup>50,52</sup>. Of note, a *post hoc* analysis of the COAPT Trial reported that the baseline use of OAC was associated with a reduction in the risk of cerebrovascular events in patients treated with mitral TEER, conversely to what was observed among patients treated with guideline-directed medical therapy alone<sup>57</sup>. Whether a part of this beneficial effect could be linked to a reduction of mitral TEER-related DRT remains to be investigated. Only limited data comparing VKAs to DOACs in such patients are available. A recent single-centre retrospective observational study which included 156 patients undergoing TMVI between 2011 and 2023 reported the use of DOACs to be associated with a significant reduction of the length of



hospital stay, as well as the risk of any bleeding at 1 year in multivariate analysis (adjusted HR 0.21, 95% CI: 0.06-0.74), without significant differences regarding thrombotic (i.e., valve thrombosis or stroke) events (adjusted HR 1.23, 95% CI: 0.42-3.65)<sup>58</sup>. Following mitral TEER, DOACs seem to be more frequently prescribed than VKAs, based on large national claims databases<sup>56,59</sup>. One retrospective study compared DOACs to VKAs after surgical or percutaneous mitral valve repair among 1,178 patients with AF and reported, after propensity score matching, a lower risk of mortality (HR 0.67, 95% CI: 0.55-0.82), ischaemic stroke (HR 0.72, 95% CI: 0.52-1.00) and bleeding (HR 0.79, 95% CI: 0.63-0.99) with DOACs<sup>60</sup>. Larger observational studies and dedicated RCTs determining the optimal antithrombotic therapy to be prescribed following transcatheter mitral or tricuspid valve repair or replacement that include patients at high risk of bleeding are certainly warranted. Finally, the role of concomitant percutaneous LAAO closure among high bleeding risk patients who cannot be treated with long-term OAC remains to be investigated.

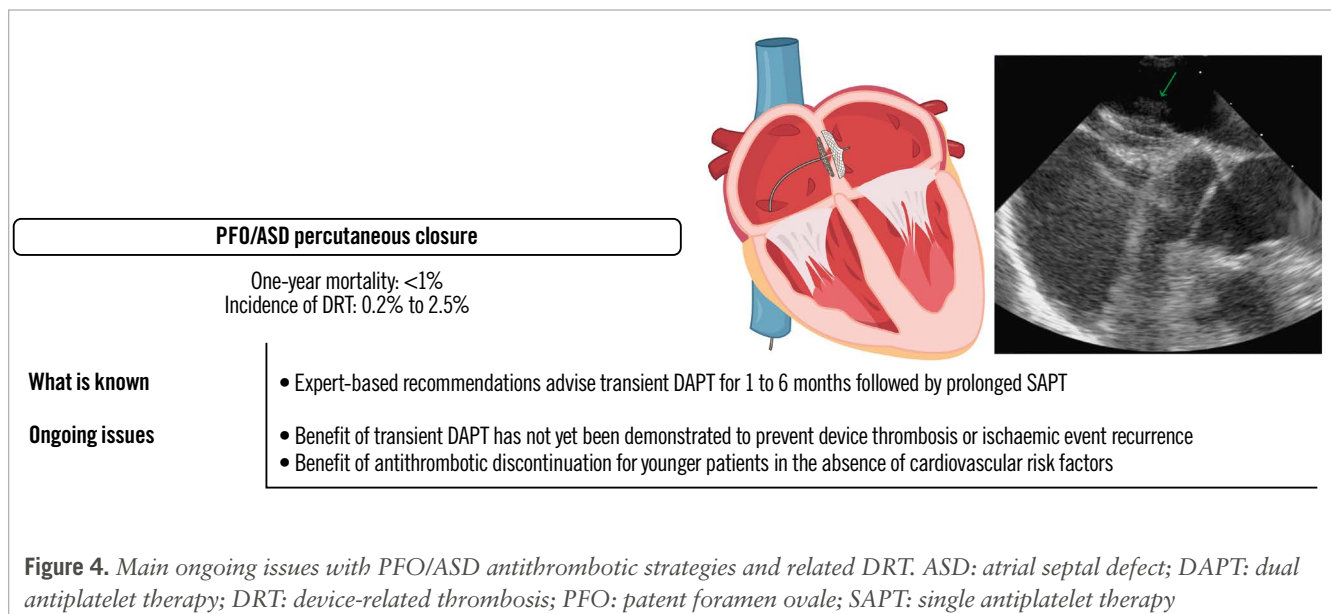
### PATENT FORAMEN OVALE OR ATRIAL SEPTAL DEFECT PERCUTANEOUS CLOSURE

There is a dearth of data from RCTs evaluating periprocedural and postprocedural antithrombotic therapy after patent foramen ovale (PFO) or atrial septal defect (ASD) closure. Expert consensus advocates transient (i.e., 1 to 6 months) DAPT followed by long-term SAPT<sup>61,62</sup>, as used in RCTs, with the aim of preventing device thrombosis during endothelialisation, a process that may be completed within 3 to 6 months after implantation and is potentially impacted by various factors including nickel hypersensitivity<sup>63,64</sup>. A single-centre observational study performed 2 decades ago reported an incidence of 2.5% during the first 6 months, occurring mostly within the first 4 weeks, using systematic transoesophageal echocardiography<sup>65</sup>. However, most of the devices used in this study are no longer available. Interestingly, there was only 1 case (0.2% of the experimental group) of device-related

cardiac thrombus reported in the RESPECT trial, 2 cases (0.5% of the experimental group) in the REDUCE trial, and none in the CLOSE or DEFENSE PFO trials<sup>66</sup>. The CANOA randomised double-blind trial compared 3-month DAPT with clopidogrel to aspirin and placebo following ASD closure in 171 patients and reported a significant impact of clopidogrel on the primary endpoint of the number of migraine days per month within 3 months of the procedure, without any significant impact in terms of ischaemic and bleeding events<sup>67</sup>.

### HOW MANY ANTIPLATELET AGENTS, IF ANY, SHOULD BE PRESCRIBED, AND FOR HOW LONG AFTER PFO OR ASD CLOSURE?

In an observational study, DAPT for 3 months versus SAPT after PFO closure among 1,532 patients (median age: 49 [IQR 40-57] years, 42.2% female) had no significant benefit on the composite of death, stroke, TIA, peripheral arterial embolism, MI, or Bleeding Academic Research Consortium (BARC) type 2 or more bleeding during 5 years of follow-up (HR 0.96, 95% CI: 0.55-1.69)<sup>66</sup>. Although these results warrant further confirmation, they challenge the current recommendations (Figure 4). In fact, stroke recurrence following PFO closure seems to be more related to other risk factors, such as persistence of significant right-to-left intracardiac shunt and comorbidities such as diabetes mellitus, age, or sex, rather than the use of DAPT compared to SAPT<sup>68-70</sup>. Consistently, although current recommendations advise for the continuation of long-term SAPT after DAPT interruption, some observational studies have reported the possibility of interrupting all antithrombotic treatment after 6 months without any alarming signals<sup>71,72</sup>. As evidence-based recommendations are lacking, clinical practices may significantly vary according to the medical speciality of the attending physician, with interventional cardiologists more likely to recommend no long-term antithrombotic treatment after PFO closure, compared to stroke neurologists, as reported by a national survey performed in the USA<sup>73</sup>. The ongoing HALTI Trial (ClinicalTrials.gov: NCT04475510)





is a single-arm observational study including patients aged  $\leq 60$  years, with 1 or fewer cardiovascular risk factors and without thrombophilia, moderate-to-severe residual right-to-left shunt or AF. In this study, patients discontinue all antiplatelet treatment 1 year after the procedure and undergo clinical and cerebral imaging evaluation at 12 and 24 months to search for any new ischaemic lesions.

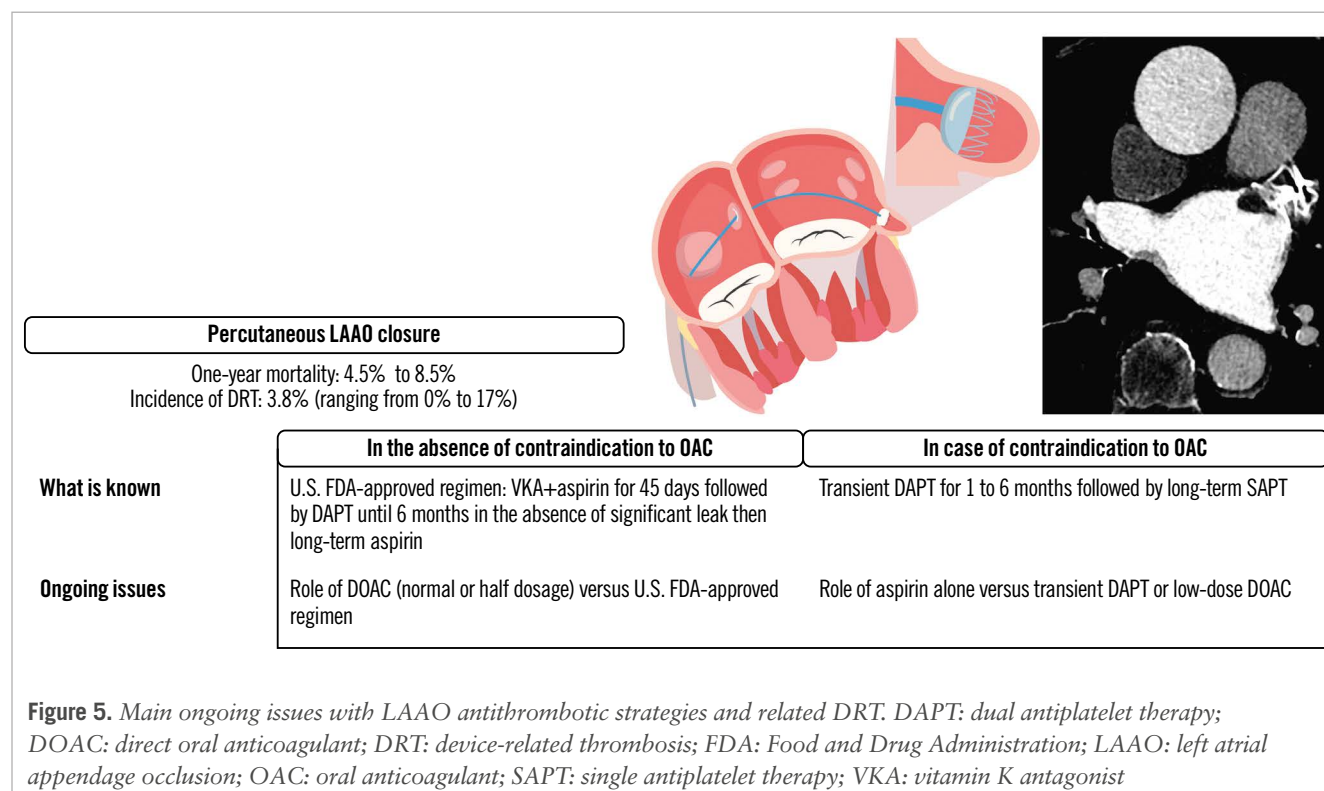
### ANTITHROMBOTIC THERAPY AFTER LEFT ATRIAL APPENDAGE OCCLUSION

Left atrial appendage occlusion was initially developed as an alternative to VKAs in patients with a relatively low risk of bleeding<sup>74</sup>. For WATCHMAN devices (Boston Scientific), the postprocedural antithrombotic regimen approved by the U.S. Food and Drug Administration (FDA) consists of VKA/DOAC with aspirin for 6 weeks or until adequate left atrial appendage (LAA) sealing (i.e., without  $\geq 5$  mm leak), followed by DAPT with clopidogrel up to 6 months, and then lifelong aspirin monotherapy. The National Cardiovascular Data Registry suggests a lack of adherence to such protocol<sup>75</sup>. In Europe, LAAO is considered for patients with AF who have contraindications for long-term OAC, with a class IIb recommendation, and may be considered, based on experts' consensus, in patients with a high risk of bleeding or willing to be treated with OAC<sup>74,76</sup>. DAPT for between 1 and 6 months, according to the bleeding risk, followed by long-term aspirin or clopidogrel may be considered<sup>74</sup>. DRT is a complication affecting  $<5\%$  of patients undergoing LAAO but is associated with a 4- to 5-fold increase in the risk of ischaemic events (Figure 5)<sup>76-79</sup>. Most of the cases of DRT seem to occur within 90 days of the procedure<sup>49,50</sup>. However, in the large international LAAC-DRT and EUROCC-DRT registries, late (i.e.,  $>6$  months) cases of DRT represented 17.9% and 36.3% of the total,

respectively<sup>80-82</sup>. The two main LAAO devices commercially available, the WATCHMAN and Amulet (Abbott) occluder devices, were compared in the SWISS-APERO trial and the larger AMULET IDE Trial<sup>83,84</sup>. Overall, the rates of DRT varied according to the timing and the methods of assessment. In the SWISS-APERO trial, the recommended antithrombotic therapy was aspirin combined with clopidogrel or OAC for 3 months followed by aspirin alone for the remaining 9 months, but this was ultimately left to the discretion of the local physician. A cardiac computed tomography angiography was performed at 45 days and 13 months and centrally adjudicated; a rate of definite or possible DRT of 3.7% was reported for Amulet devices and 9.9% for WATCHMAN devices (RR 0.38, 95% CI: 0.12-1.17), and 2.4% for Amulet devices and 3.8% for WATCHMAN devices (RR 0.63, 95% CI: 0.11-3.70), respectively<sup>84,85</sup>. At 45 days, a transoesophageal echocardiography was also performed, and a rate of DRT of 2.1% was reported for Amulet devices and 5.5% for WATCHMAN devices (RR 0.38, 95% CI: 0.08-1.93). In the AMULET IDE Trial, the FDA-approved regimen was recommended for patients treated with the WATCHMAN devices, while patients treated with the Amulet devices were recommended to be treated with aspirin plus clopidogrel or OAC at the discretion of the investigator. The rate of DRT at 18 months was 3.3% for the Amulet devices and 4.5% with the WATCHMAN devices<sup>83</sup>.

### WHICH ANTITHROMBOTIC REGIMEN SHOULD BE USED AFTER LAAO WHEN BLEEDING RISK IS HIGH?

Post-LAAO antithrombotic treatment directly affects the risk of DRT and subsequent ischaemic complications. However, data mostly derived from observational studies and a recent network meta-analysis of 41 studies comprising



12,451 patients reported monotherapy with DOACs to have the highest likelihood of reducing the incidence of thromboembolic events and major bleeding, while DAPT was associated with a lower incidence of thromboembolic events compared to SAPT<sup>86</sup>. In a prospective non-randomised study, a half-dose of DOACs was associated with a significant reduction in the risk of DRT and thromboembolic and bleeding events compared to the FDA-approved regimen (HR 0.10, 95% CI: 0.02-0.43)<sup>87</sup>. The exploratory RCT ADRIFT compared 3-month DAPT and rivaroxaban alone (either 10 mg q.d. or 15 mg q.d.)<sup>88</sup>. The study was not powered to

evaluate a clinical endpoint, but the only two cases of DRT confirmed by the blinded imaging core laboratory occurred in the DAPT group. Finally, the ADALA trial compared low-dose apixaban (i.e., 2.5 mg b.i.d.) to 3-month DAPT<sup>89</sup>. The study was prematurely interrupted after the inclusion of only 90 of the planned 160 patients and reported low-dose apixaban to be associated with a significant reduction in the composite of thromboembolic events, device thrombosis and major bleeding at 3 months (HR 0.19, 95% CI: 0.04-0.88). **Table 2** details the main ongoing RCTs evaluating post-LAAO antithrombotic regimens.

**Table 2. Main ongoing randomised controlled trials evaluating antithrombotic regimens after LAAO.**

Study title, clinical trial registration	Number of planned inclusions	Masking	Antithrombotic regimen evaluated	Primary endpoint
ANDES NCT03568890	510	Open-label	Randomisation is performed after successful LAAO to either: - normal dosage of DOAC according to guidelines for 8 weeks - DAPT for 8 weeks	DRT evaluated by TOE at 8 weeks after the procedure
SAFE-LAAC NCT03445949	200	Open-label	Randomisation is performed after successful LAAO to either: - DAPT for 30 days followed by SAPT - DAPT for 6 months	Composite of all-cause or CV death, ischaemic stroke, TIA, peripheral embolism, MI, or left atrial appendage thrombus at 17 months after randomisation
ASPIRIN-LAAO NCT03821883	1,120	Double-blinded	Randomisation is performed 6 months after successful LAAO to either: - aspirin - placebo	Number of participants with CV death, stroke, systemic embolism, acute coronary syndrome, coronary or periphery artery disease requiring revascularisation, and major bleeding at 24 months after randomisation
FADE-DRT NCT04502017	360	Open-label	Randomisation is performed after successful LAAO to either: - U.S. FDA-approved regimen - OAC for 6 weeks, followed by DAPT (for clopidogrel responder) or aspirin+half-dose OAC (for clopidogrel non-responders) for 6 months, then aspirin alone - half-dose DOAC	- Composite of stroke, systemic embolism, and DRT at 1 year - Composite of major bleeding at 1 year
RECORD-III NCT05960721	4,220	Open-label	Randomisation is performed after successful LAAO to either: - low dose of rivaroxaban based on HAS-BLED score. If score <3, 15 mg q.d. for 3 months, then 10 mg q.d.; if ≥3, 10 mg q.d. for 3 months, then 2.5 mg b.i.d. - guideline-determined medication therapy based on HAS-BLED score: if score <3, rivaroxaban 15 mg q.d.+aspirin for 3 months then aspirin alone; if ≥3, DAPT for 3 months then aspirin alone	Rate of the composite endpoint of death, stroke, systemic embolism, and BARC type 3 or 5 bleeding events at 24 months from randomisation
ARMYDA-AMULET NCT05554822	574	Open-label	Randomisation is performed after successful LAAO to either: - aspirin alone - DAPT for 3 months then aspirin alone	Composite of death, DRT (at 3- or 6-month TOE), ischaemic stroke, systemic embolism, or BARC ≥3 bleeding at 6 months after the procedure
Efficacy of Different Anti-Thrombotic Strategies on the Incidence of Silent Cerebral Embolism After Percutaneous Left Atrial Appendage Occlusion: a Randomized Control Trial NCT05671276	150	Open-label	Randomisation is performed 45 days after successful LAAO to either: - DAPT from 45 days to 6 months then aspirin alone - rivaroxaban 10 q.d.	Incidence of new silent cerebral embolism by cerebral magnetic resonance imaging at 6 months

BARC: Bleeding Academic Research Consortium; CV: cardiovascular; DAPT: dual antiplatelet therapy (aspirin+clopidogrel); DOAC: direct oral anticoagulant; DRT: device-related thrombosis; FDA: Food and Drug Administration; LAAO: left atrial appendage occlusion; MI: myocardial infarction; OAC: oral anticoagulant; SAPT: single antiplatelet therapy; TIA transient ischaemic attack; TOE: transoesophageal echocardiography

## Conclusions

Much more remains to be done in the field of antithrombotic therapy for transcatheter interventions to better determine the incidence and risk factors of device-related thrombosis. In contrast to the field of TAVI where various RCTs have helped to identify the optimal antithrombotic therapy based on patient characteristics, evidence-based recommendations are still lacking for all other types of transcatheter interventions. Available results suggest that although DRT is a relatively common and potentially severe complication, systematic use of a potent antithrombotic therapy or association of various agents may result in an intolerable bleeding risk, emphasising the need for tailored approaches for each type of transcatheter intervention and patient characteristic to identify the fine balance between safety and efficacy.

## Authors' affiliations

1. Sorbonne Université, ACTION Group, INSERM UMRS 1166, Institut de Cardiologie (AP-HP), Paris, France; 2. Quebec Heart & Lung Institute, Laval University, Quebec City, QC, Canada; 3. Department of Cardiology, St. Antonius Hospital, Nieuwegein, the Netherlands; 4. Cardiovascular Research Institute Maastricht (CARIM), Maastricht, the Netherlands; 5. Department of Cardiology, Bern University Hospital (Inselspital), University of Bern, Bern, Switzerland; 6. Division of Cardiology, University of Florida College of Medicine, Jacksonville, FL, USA

## Conflict of interest statement

J-P. Collet reports support from AstraZeneca, Boston Scientific, Bristol-Myers Squibb, COR2ED, Lead-Up, Medtronic, and WebMD. J. Rodés-Cabau reports institutional research grants from Edwards Lifesciences, Medtronic, Boston Scientific, and Abbott; and consultant/speaker fees from Edwards Lifesciences and Medtronic. J.M. Ten Berg reports grants from AstraZeneca and from the St. Antonius research fund; and personal fees from Boehringer Ingelheim, AstraZeneca, Bayer, and Ferrer. S. Windecker reports research, travel or educational grants to the institution without personal remuneration from Abbott, Abiomed, Amgen, AstraZeneca, Bayer, B. Braun, Biotronik, Boehringer Ingelheim, Boston Scientific, Bristol-Myers Squibb, Cardinal Health, Cardiovalve, Cordis Medical, CorFlow Therapeutics, CSL Behring, Daiichi Sankyo, Edwards Lifesciences, Farapulse Inc., Fumedica, Guerbet, Idorsia, Inari Medical, InfraRedx, Janssen-Cilag, Johnson & Johnson, MedAlliance, Medicure, Medtronic, Merck Sharp & Dohme, Miracor Medical, Monarq, Novartis, Novo Nordisk, Organon, OrPha Swiss, Pharming Group N.V., Pfizer, Polares, Regeneron, Sanofi-Aventis, Servier, Sinomed, Terumo, Vifor, and V-Wave; and he has served as an advisory board member and/or member of the steering/executive group of trials funded by Abbott, Abiomed, Amgen, AstraZeneca, Bayer, Boston Scientific, Biotronik, Bristol-Myers Squibb, Edwards Lifesciences, MedAlliance, Medtronic, Novartis, Polares, Recardio, Sinomed, Terumo, and V-Wave, with payments to the institution but no personal payments; he is also a member of the steering/executive committee group of several investigator-initiated trials that receive funding

from industry without impact on his personal remuneration. D.J. Angiolillo declares that he has received consulting fees or honoraria from Abbott, Amgen, AstraZeneca, Bayer, Biosensors, Boehringer Ingelheim, Bristol-Myers Squibb, Chiesi, CSL Behring, Daiichi Sankyo, Eli Lilly, Haemonetics, Janssen, Merck, Novartis, Novo Nordisk, PhaseBio, PLx Pharma, Pfizer, Sanofi, and Vectura; he also declares that his institution has received research grants from Amgen, AstraZeneca, Bayer, Biosensors, CeloNova, CSL Behring, Daiichi Sankyo, Eisai, Eli Lilly, Gilead, Idorsia, Janssen, Matsutani Chemical Industry Co., Merck, Novartis, and the Scott R. MacKenzie Foundation. G. Montalescot reports during the past 2 years research grants to the institution or consulting/lecture fees from Abbott, Amgen, AstraZeneca, Bayer, Boehringer Ingelheim, Boston Scientific, Bristol-Myers Squibb, CellProthera, CSL Behring, Europa, Idorsia, IRIS-Servier, Medtronic, MSD, Novartis, Pfizer, Quantum Genomics, and Sanofi-Aventis. P. Guedeney has no conflicts of interest to declare.

## References

- Guedeney P, Mehran R, Collet JP, Claessen BE, Ten Berg J, Dangas GD. Antithrombotic Therapy After Transcatheter Aortic Valve Replacement. *Circ Cardiovasc Interv.* 2019;12:e007411.
- Capodanno D, Collet JP, Dangas G, Montalescot G, Ten Berg JM, Windecker S, Angiolillo DJ. Antithrombotic Therapy After Transcatheter Aortic Valve Replacement. *JACC Cardiovasc Interv.* 2021;14:1688-703.
- Nishimura RA, Otto CM, Bonow RO, Carabello BA, Erwin JP 3rd, Guyton RA, O'Gara PT, Ruiz CE, Skubas NJ, Sorajja P, Sundt TM 3rd, Thomas JD; American College of Cardiology/American Heart Association Task Force on Practice Guidelines. 2014 AHA/ACC guideline for the management of patients with valvular heart disease: executive summary: a report of the American College of Cardiology/American Heart Association Task Force on Practice Guidelines. *J Am Coll Cardiol.* 2014;63:2438-88.
- Guedeney P, Sorrentino S, Mesnier J, De Rosa S, Indolfi C, Zeitouni M, Kerneis M, Silvain J, Montalescot G, Collet JP. Single Versus Dual Antiplatelet Therapy Following TAVR: A Systematic Review and Meta-Analysis of Randomized Controlled Trials. *JACC Cardiovasc Interv.* 2021;14:234-6.
- Guedeney P, Roule V, Mesnier J, Chapelle C, Portal JJ, Laporte S, Ollier E, Zeitouni M, Kerneis M, Procopi N, Barthelemy O, Sorrentino S, Mihalovic M, Silvain J, Vicaut E, Montalescot G, Collet JP. Antithrombotic therapy and cardiovascular outcomes after transcatheter aortic valve implantation in patients without indications for chronic oral anticoagulation: a systematic review and network meta-analysis of randomized controlled trials. *Eur Heart J Cardiovasc Pharmacother.* 2023;9:251-61.
- Rodés-Cabau J, Masson JB, Welsh RC, Garcia Del Blanco B, Pelletier M, Webb JG, Al-Qoofi F, Génereux P, Maluenda G, Thoenes M, Paradis JM, Chamandi C, Serra V, Dumont E, Côté M. Aspirin Versus Aspirin Plus Clopidogrel as Antithrombotic Treatment Following Transcatheter Aortic Valve Replacement With a Balloon-Expandable Valve: The ARTE (Aspirin Versus Aspirin + Clopidogrel Following Transcatheter Aortic Valve Implantation) Randomized Clinical Trial. *JACC Cardiovasc Interv.* 2017;10:1357-65.
- Brouwer J, Nijenhuis VJ, Delewi R, Hermanides RS, Holvoet W, Dubois CLF, Frambach P, De Bruyne B, van Houwelingen GK, Van Der Heyden JAS, Toušek P, van der Kley F, Buysschaert I, Schotborgh CE, Ferdinande B, van der Harst P, Roosen J, Peper J, Thielen FWF, Veenstra L, Chan Pin Yin DRPP, Swaans MJ, Rensing BJWM, van 't Hof AWJ, Timmers L, Kelder JC, Stella PR, Baan J, Ten Berg JM. Aspirin with or without Clopidogrel after Transcatheter Aortic-Valve Implantation. *N Engl J Med.* 2020;383:1447-57.
- Brouwer J, Nijenhuis VJ, Rodés-Cabau J, Stabile E, Barbanti M, Costa G, Mahmoodi BK, Ten Berg JM. Aspirin Alone Versus Dual Antiplatelet Therapy After Transcatheter Aortic Valve Implantation: A Systematic

- Review and Patient-Level Meta-Analysis. *J Am Heart Assoc.* 2021;10:e019604.
9. Baumgartner H, Falk V, Bax JJ, De Bonis M, Hamm C, Holm PJ, Jung B, Lancellotti P, Lansac E, Rodriguez Muñoz D, Rosenhek R, Sjögren J, Tornos Mas P, Vahanian A, Walther T, Wendler O, Windecker S, Zamorano JL; ESC Scientific Document Group. 2017 ESC/EACTS Guidelines for the management of valvular heart disease. *Eur Heart J.* 2017;38:2739-91.
  10. Writing Committee Members; Otto CM, Nishimura RA, Bonow RO, Carabello BA, Erwin JP 3rd, Gentile F, Jneid H, Krieger EV, Mack M, McLeod C, O'Gara PT, Rigolin VH, Sundt TM 3rd, Thompson A, Toly C. 2020 ACC/AHA Guideline for the Management of Patients With Valvular Heart Disease: Executive Summary: A Report of the American College of Cardiology/American Heart Association Joint Committee on Clinical Practice Guidelines. *J Am Coll Cardiol.* 2021;77:450-500.
  11. Ten Berg J, Sibbing D, Rocca B, Van Belle E, Chevalier B, Collet JP, Dudek D, Gilard M, Gorog DA, Grapsa J, Grove EL, Lancellotti P, Petronio AS, Rubboli A, Torracca L, Vilahur G, Witkowski A, Mehilli J. Management of antithrombotic therapy in patients undergoing transcatheter aortic valve implantation: a consensus document of the ESC Working Group on Thrombosis and the European Association of Percutaneous Cardiovascular Interventions (EAPCI), in collaboration with the ESC Council on Valvular Heart Disease. *Eur Heart J.* 2021;42:2265-9.
  12. Vahanian A, Beyersdorf F, Praz F, Milojevic M, Baldus S, Bauersachs J, Capodanno D, Conradi L, De Bonis M, De Paulis R, Delgado V, Freemantle N, Haugaa KH, Jeppsson A, Jüni P, Pierard L, Prendergast BD, Sádaba JR, Tribouilloy C, Wojakowski W. 2021 ESC/EACTS Guidelines for the management of valvular heart disease. *EuroIntervention.* 2022;17:e1126-96.
  13. Makkar RR, Fontana G, Jilaihawi H, Chakravarty T, Kofoed KF, De Backer O, Asch FM, Ruiz CE, Olsen NT, Trento A, Friedman J, Berman D, Cheng W, Kashif M, Jelnin V, Klinger CA, Guo H, Pichard AD, Weissman NJ, Kapadia S, Manasse E, Bhatt DL, Leon MB, Søndergaard L. Possible Subclinical Leaflet Thrombosis in Bioprosthetic Aortic Valves. *N Engl J Med.* 2015;373:2015-24.
  14. Bogyi M, Scherthaner RE, Loewe C, Gager GM, Dizdarevic AM, Kronberger C, Postula M, Legutko J, Velagapudi P, Hengstenberg C, Siller-Matula JM. Subclinical Leaflet Thrombosis After Transcatheter Aortic Valve Replacement: A Meta-Analysis. *JACC Cardiovasc Interv.* 2021;14:2643-56.
  15. Roule V, Guedeney P, Silvain J, Beygui F, Zeitouni M, Sorrentino S, Kerneis M, Barthelemy O, Beaupré F, Portal JJ, Vicaut E, Montalescot G, Collet JP. Bioprosthetic leaflet thrombosis and reduced leaflet motion after transcatheter aortic valve replacement: A systematic review and meta-analysis. *Arch Cardiovasc Dis.* 2023;116:563-71.
  16. Rashid HN, Gooley RP, Nerlekar N, Ihdahid AR, McCormick LM, Nasis A, Cameron JD, Brown AJ. Bioprosthetic aortic valve leaflet thrombosis detected by multidetector computed tomography is associated with adverse cerebrovascular events: a meta-analysis of observational studies. *EuroIntervention.* 2018;13:e1748-55.
  17. Bogyi M, Siller-Matula JM. Reply: Prosthesis Type-Associated Risk of Subclinical Leaflet Thrombosis. *JACC Cardiovasc Interv.* 2022;15:676-7.
  18. Overtchouk P, Guedeney P, Rouanet S, Verhoye JP, Lefevre T, Van Belle E, Eltchaninoff H, Gilard M, Leprince P, Iung B, Barthelemy O, Le Breton H, Souteyrand G, Vicaut E, Montalescot G, Collet JP. Long-Term Mortality and Early Valve Dysfunction According to Anticoagulation Use: The FRANCE TAVI Registry. *J Am Coll Cardiol.* 2019;73:13-21.
  19. Guedeney P, Huchet F, Manigold T, Overtchouk P, Rouanet S, Balagny P, Leprince P, Lebreton G, Letocart V, Barthelemy O, Vicaut E, Montalescot G, Guerin P, Collet JP; ACTION Study Group. Effect of oral anticoagulation on clinical outcomes and haemodynamic variables after successful transcatheter aortic valve implantation. *Arch Cardiovasc Dis.* 2020;113:341-9.
  20. Koren O, Patel V, Chakravarty T, Jilaihawi H, Gupta A, Sadri S, Makkar RR. Leaflet thrombosis in transcatheter aortic valve intervention: mechanisms, prevention, and treatment options. *Front Cardiovasc Med.* 2023;10:1249604.
  21. Rosseel L, De Backer O, Søndergaard L. Clinical Valve Thrombosis and Subclinical Leaflet Thrombosis Following Transcatheter Aortic Valve Replacement: Is There a Need for a Patient-Tailored Antithrombotic Therapy? *Front Cardiovasc Med.* 2019;6:44.
  22. Ferstl P, Achenbach S, Marwan M, Bittner DO. Comparison of oral anticoagulation by vitamin-K antagonists and non-vitamin-K antagonists for treatment of leaflet thickening after transcatheter aortic valve implantation (TAVI). *Int J Cardiol.* 2023;386:104-8.
  23. Jose J, Sulimov DS, El-Mawardy M, Sato T, Allali A, Holy EW, Becker B, Landt M, Kebernik J, Schwarz B, Richardt G, Abdel-Wahab M. Clinical Bioprosthetic Heart Valve Thrombosis After Transcatheter Aortic Valve Replacement: Incidence, Characteristics, and Treatment Outcomes. *JACC Cardiovasc Interv.* 2017;10:686-97.
  24. Dargas GD, Tijssen JGP, Wöhrle J, Søndergaard L, Gilard M, Möllmann H, Makkar RR, Herrmann HC, Giustino G, Baldus S, De Backer O, Guimarães AHC, Gullestad L, Kini A, von Lewinski D, Mack M, Moreno R, Schäfer U, Seeger J, Tchétché D, Thomitzek K, Valgimigli M, Vranckx P, Welsh RC, Wildgoose P, Volkl AA, Zazula A, van Amsterdam RGM, Mehran R, Windecker S; GALILEO Investigators. A Controlled Trial of Rivaroxaban after Transcatheter Aortic-Valve Replacement. *N Engl J Med.* 2020;382:120-9.
  25. Collet JP, Van Belle E, Thiele H, Berti S, Lhermusier T, Manigold T, Neumann FJ, Gilard M, Attias D, Beygui F, Cequier A, Alfonso F, Aubry P, Baronnet F, Ederhy S, Kasty M, Kerneis M, Barthelemy O, Lefèvre T, Leprince P, Redheuil A, Henry P, Portal JJ, Vicaut E, Montalescot G; ATLANTIS Investigators of the ACTION Group. Apixaban vs. standard of care after transcatheter aortic valve implantation: the ATLANTIS trial. *Eur Heart J.* 2022;43:2783-97.
  26. De Backer O, Dargas GD, Jilaihawi H, Leipsic JA, Terkelsen CJ, Makkar R, Kini AS, Veien KT, Abdel-Wahab M, Kim WK, Balan P, Van Mieghem N, Mathiassen ON, Jeger RV, Arnold M, Mehran R, Guimarães AHC, Nørgaard BL, Kofoed KF, Blanke P, Windecker S, Søndergaard L; GALILEO-4D Investigators. Reduced Leaflet Motion after Transcatheter Aortic-Valve Replacement. *N Engl J Med.* 2020;382:130-9.
  27. Montalescot G, Redheuil A, Vincent F, Desch S, De Benedictis M, Eltchaninoff H, Trenk D, Serfaty JM, Charpentier E, Bouazizi K, Prigent M, Guedeney P, Salloum T, Berti S, Cequier A, Lefèvre T, Leprince P, Silvain J, Van Belle E, Neumann FJ, Portal JJ, Vicaut E, Collet JP; ATLANTIS Investigators of the ACTION Group. Apixaban and Valve Thrombosis After Transcatheter Aortic Valve Replacement: The ATLANTIS-4D-CT Randomized Clinical Trial Substudy. *JACC Cardiovasc Interv.* 2022;15:1794-804.
  28. Park DW, Ahn JM, Kang DY, Kim KW, Koo HJ, Yang DH, Jung SC, Kim B, Wong YTA, Lam CCS, Yin WH, Wei J, Lee YT, Kao HL, Lin MS, Ko TY, Kim WJ, Kang SH, Yun SC, Lee SA, Ko E, Park H, Kim DH, Kang JW, Lee JH, Park SJ; ADAPT-TAVR Investigators. Edoxaban Versus Dual Antiplatelet Therapy for Leaflet Thrombosis and Cerebral Thromboembolism After TAVR: The ADAPT-TAVR Randomized Clinical Trial. *Circulation.* 2022;146:466-79.
  29. Mack MJ, Leon MB, Thourani VH, Pibarot P, Hahn RT, Genereux P, Kodali SK, Kapadia SR, Cohen DJ, Pocock SJ, Lu M, White R, Szerlip M, Ternacle J, Malaisrie SC, Herrmann HC, Szeto WY, Russo MJ, Babaliaros V, Smith CR, Blanke P, Webb JG, Makkar R; PARTNER 3 Investigators. Transcatheter Aortic-Valve Replacement in Low-Risk Patients at Five Years. *N Engl J Med.* 2023;389:1949-60.
  30. Harrington J, Piccini JP, Alexander JH, Granger CB, Patel MR. Clinical Evaluation of Factor XIa Inhibitor Drugs: JACC Review Topic of the Week. *J Am Coll Cardiol.* 2023;81:771-9.
  31. Kobari Y, Inohara T, Saito T, Yoshijima N, Tanaka M, Tsuruta H, Yashima F, Shimizu H, Fukuda K, Naganuma T, Mizutani K, Yamawaki M, Tada N, Yamanaka F, Shirai S, Tabata M, Ueno H, Takagi K, Watanabe Y, Yamamoto M, Hayashida K. Aspirin Versus Clopidogrel as Single Antithrombotic Therapy After Transcatheter Aortic Valve Replacement: Insight From the OCEAN-TAVI Registry. *Circ Cardiovasc Interv.* 2021;14:e010097.
  32. Jimenez Diaz VA, Tello-Montoliu A, Moreno R, Cruz Gonzalez I, Baz Alonso JA, Romaguera R, Molina Navarro E, Juan Salvadores P, Paredes Galan E, De Miguel Castro A, Bastos Fernandez G, Ortiz Saez A, Fernandez Barreira S, Raposeiras Roubin S, Ocampo Miguez J, Serra Peñaranda A, Valdes Chavarri M, Cequier Fillat A, Calvo Iglesias F, Iñiguez Romo A. Assessment of Platelet REACTivity After Transcatheter Aortic Valve Replacement: The REAC-TAVI Trial. *JACC Cardiovasc Interv.* 2019;12:22-32.

33. Kobari Y, Inohara T, Tsuruta H, Yashima F, Shimizu H, Fukuda K, Naganuma T, Mizutani K, Yamawaki M, Tada N, Yamanaka F, Shirai S, Tabata M, Ueno H, Takagi K, Watanabe Y, Yamamoto M, Hayashida K. No Antithrombotic Therapy After Transcatheter Aortic Valve Replacement: Insight From the OCEAN-TAVI Registry. *JACC Cardiovasc Interv.* 2023;16:79-91.
34. Auffret V, Guedeney P, Leurent G, Didier R. Antithrombotic After TAVR: No Treatment, No Problem? *JACC Cardiovasc Interv.* 2023;16:92-3.
35. Mack MJ, Leon MB, Thourani VH, Makkar R, Kodali SK, Russo M, Kapadia SR, Malaisrie SC, Cohen DJ, Pibarot P, Leipsic J, Hahn RT, Blanke P, Williams MR, McCabe JM, Brown DL, Babaliaros V, Goldman S, Szeto WY, Genevex P, Pershad A, Pocock SJ, Alu MC, Webb JG, Smith CR; PARTNER 3 Investigators. Transcatheter Aortic-Valve Replacement with a Balloon-Expandable Valve in Low-Risk Patients. *N Engl J Med.* 2019;380:1695-705.
36. Nijenhuis VJ, Brouwer J, Delewi R, Hermanides RS, Holvoet W, Dubois CLF, Frambach P, De Bruyne B, van Houwelingen GK, Van Der Heyden JAS, Toušek P, van der Kley F, Buyschaert I, Schotborgh CE, Ferdinande B, van der Harst P, Roosen J, Peper J, Thielen FWF, Veenstra L, Chan Pin Yin DRPP, Swaans MJ, Rensing BJWM, van 't Hof AWJ, Timmers L, Kelder JC, Stella PR, Baan J, Ten Berg JM. Anticoagulation with or without Clopidogrel after Transcatheter Aortic-Valve Implantation. *N Engl J Med.* 2020;382:1696-707.
37. Douketis JD, Spyropoulos AC, Murad MH, Arcelus JI, Dager WE, Dunn AS, Fargo RA, Levy JH, Samama CM, Shah SH, Sherwood MW, Tafur AJ, Tang LV, Moores LK. Perioperative Management of Antithrombotic Therapy: An American College of Chest Physicians Clinical Practice Guideline. *Chest.* 2022;162:e207-43.
38. Holmes DR Jr, Mack MJ, Kaul S, Agnihotri A, Alexander KP, Bailey SR, Calhoun JH, Carabello BA, Desai MY, Edwards FH, Francis GS, Gardner TJ, Kappetein AP, Linderbaum JA, Mukherjee C, Mukherjee D, Otto CM, Ruiz CE, Sacco RL, Smith D, Thomas JD. 2012 ACCF/AATS/SCAI/STS expert consensus document on transcatheter aortic valve replacement. *J Am Coll Cardiol.* 2012;59:1200-54.
39. Mangner N, Crusius L, Haussig S, Woitek FJ, Kiefer P, Stachel G, Leontyev S, Schlotter F, Spindler A, Höllriegel R, Hommel J, Thiele H, Borger MA, Holzhey D, Linke A. Continued Versus Interrupted Oral Anticoagulation During Transfemoral Transcatheter Aortic Valve Implantation and Impact of Postoperative Anticoagulant Management on Outcome in Patients With Atrial Fibrillation. *Am J Cardiol.* 2019;123:1134-41.
40. van Ginkel DJ, Bor WL, Dubois CLF, Aarts HM, Rooijackers MJP, van Bergeijk KH, Rosseel L, Veenstra L, De Backer O, Van Mieghem NM, van der Kley F, Wilgenhof A, Leonora R, Halim J, Schotborgh CE, Barbato E, Van Der Heyden JAS, Frambach P, Ferdinande B, Mylotte D, Fabris E, Rensing BJWM, Timmers L, Swaans MJ, Brouwer J, Nijenhuis VJ, Peper J, Vriesendorp PA, de Laat B, Nivivaggi M, Stragier H, Voskuil M, Ijsselmuiden AJJ, Hermanides RS, Agostoni P, van 't Hof AWJ, Wykrzykowska JJ, van Royen N, Delewi R, Ten Berg JM. Periprocedural continuation versus interruption of oral anticoagulant drugs during transcatheter aortic valve implantation: rationale and design of the POPular PAUSE TAVI trial. *EuroIntervention.* 2023;19:766-71.
41. Tanawuttiwat T, Stebbins A, Marquis-Gravel G, Vemulapalli S, Kosinski AS, Cheng A. Use of Direct Oral Anticoagulant and Outcomes in Patients With Atrial Fibrillation after Transcatheter Aortic Valve Replacement: Insights From the STS/ACC TVT Registry. *J Am Heart Assoc.* 2022;11:e023561.
42. Van Mieghem NM, Unverdorben M, Hengstenberg C, Möllmann H, Mehran R, López-Otero D, Nombela-Franco L, Moreno R, Nordbeck P, Thiele H, Lang I, Zamorano JL, Shawl F, Yamamoto M, Watanabe Y, Hayashida K, Hambrecht R, Meincke F, Vranckx P, Jin J, Boersma E, Rodés-Cabau J, Ohlmann P, Capranzano P, Kim HS, Pilgrim T, Anderson R, Baber U, Duggal A, Laeis P, Lanz H, Chen C, Valgimigli M, Veltkamp R, Saito S, Dangas GD; ENVISAGE-TAVI AF Investigators. Edoxaban versus Vitamin K Antagonist for Atrial Fibrillation after TAVR. *N Engl J Med.* 2021;385:2150-60.
43. Kapadia SR, Krishnaswamy A, Whisenant B, Potluri S, Iyer V, Aragon J, Gideon P, Strote J, Leonardi R, Agarwal H, Larrain G, Sanchez C, Panaich SS, Harvey J, Vahl T, Menon V, Wolski K, Wang Q, Leon MB. Concomitant Left Atrial Appendage Occlusion and Transcatheter Aortic Valve Replacement Among Patients With Atrial Fibrillation. *Circulation.* 2024;149:734-43.
44. Al-Kassou B, Kandt J, Lohde L, Shamekhi J, Sedaghat A, Tabata N, Weber M, Sugiura A, Fimmers R, Werner N, Grube E, Treede H, Nickenig G, Sinning JM. Safety and Efficacy of Protamine Administration for Prevention of Bleeding Complications in Patients Undergoing TAVR. *JACC Cardiovasc Interv.* 2020;13:1471-80.
45. Al-Kassou B, Veulemans V, Shamekhi J, Maier O, Piayda K, Zeus T, Aksoy A, Zietzer A, Meertens M, Mauri V, Weber M, Sinning JM, Grube E, Adam M, Bakhtyari F, Zimmer S, Baldus S, Kelm M, Nickenig G, Sedaghat A. Optimal protamine-to-heparin dosing ratio for the prevention of bleeding complications in patients undergoing TAVR-A multicenter experience. *Clin Cardiol.* 2023;46:67-75.
46. Zbroński K, Grodecki K, Gozdowska R, Ostrowska E, Wysińska J, Rymuza B, Scisło P, Wiliński R, Kochman J, Filipiak KJ, Opolski G, Huczek Z. Protamine sulfate during transcatheter aortic valve implantation (PS TAVI) - a single-center, single-blind, randomized placebo-controlled trial. *Kardiol Pol.* 2021;79:995-1002.
47. Jililhawi H. Transcatheter heart valve thrombosis on the mitral stage: "The Tempest" or "Much Ado About Nothing"? *EuroIntervention.* 2021;16:1386-7.
48. Kikoïne J, Urena M, Chong Nguyen C, Fischer Q, Carrasco JL, Brochet E, Ducrocq G, Vahanian A, Iung B, Himbert D. Predictors and clinical impact of thrombosis after transcatheter mitral valve implantation using balloon-expandable bioprostheses. *EuroIntervention.* 2021;16:1455-62.
49. Akodad M, Trpkov C, Cheung A, Ye J, Chatfield AG, Alosail A, Besola L, Yu M, Leipsic JA, Lounes Y, Meier D, Yang C, Nestelberger T, Tzimas G, Sathananthan J, Wood DA, Moss RR, Blanke P, Sathananthan G, Webb JG. Valve-in-Valve Transcatheter Mitral Valve Replacement: A Large First-in-Human 13-Year Experience. *Can J Cardiol.* 2023;39:1959-70.
50. Stone GW, Lindenfeld J, Abraham WT, Kar S, Lim DS, Mishell JM, Whisenant B, Grayburn PA, Rinaldi M, Kapadia SR, Rajagopal V, Sarembock IJ, Brieke A, Marx SO, Cohen DJ, Weissman NJ, Mack MJ; COAPT Investigators. Transcatheter Mitral-Valve Repair in Patients with Heart Failure. *N Engl J Med.* 2018;379:2307-18.
51. Mahmood M, Ghumman GM, Ahsan M, Singh H, Avula SR, Alo S, Al-Dabbas M, Ali SS, Kabour A. Management of Right Atrial Thrombus During MitraClip Implantation: A Case Report and Review of Literature. *Cardiovasc Revasc Med.* 2023;47:97-9.
52. Sorajja P, Whisenant B, Hamid N, Naik H, Makkar R, Tadros P, Price MJ, Singh G, Fam N, Kar S, Schwartz JG, Mehta S, Bae R, Sekaran N, Warner T, Makar M, Zorn G, Spinner EM, Trusty PM, Benza R, Jorde U, McCarthy P, Thourani V, Tang GHL, Hahn RT, Adams DH; TRILUMINATE Pivotal Investigators. Transcatheter Repair for Patients with Tricuspid Regurgitation. *N Engl J Med.* 2023;388:1833-42.
53. Lurz P, Besler C, Schmitz T, Bekeredian R, Nickenig G, Möllmann H, von Bardeleben RS, Schmeisser A, Atmowihardjo I, Estevez-Loureiro R, Lubos E, Heitkemper M, Huang D, Lapp H, Donal E; bRIGHT PAS Principal Investigators. Short-Term Outcomes of Tricuspid Edge-to-Edge Repair in Clinical Practice. *J Am Coll Cardiol.* 2023;82:281-91.
54. McElhinney DB, Aboulhosn JA, Dvir D, Whisenant B, Zhang Y, Eicken A, Ribichini F, Tzifa A, Hainstock MR, Martin MH, Kornowski R, Schubert S, Latib A, Thomson JDR, Torres AJ, Meadows J, Delaney JW, Guerrero ME, Salizzoni S, El-Said H, Finkelstein A, George I, Gwillig M, Alvarez-Fuente M, Lamers L, Cheema AN, Kreuzer JN, Rudolph T, Hildick-Smith D, Cabalka AK; VIVID Registry. Mid-Term Valve-Related Outcomes After Transcatheter Tricuspid Valve-in-Valve or Valve-in-Ring Replacement. *J Am Coll Cardiol.* 2019;73:148-57.
55. Kodali S, Hahn RT, Makkar R, Makar M, Davidson CJ, Puthumana JJ, Zahr F, Chadderdon S, Fam N, Ong G, Yadav P, Thourani V, Vannan MA, O'Neill WW, Wang DD, Tchetché D, Dumonteil N, Bonfils L, Lepage L, Smith R, Grayburn PA, Sharma RP, Haeffle C, Babaliaros V, Gleason PT, Elmariah S, Inglessis-Azuaje I, Passeri J, Herrmann HC, Silvestry FE, Lim S, Fowler D, Webb JG, Moss R, Modine T, Lafitte S, Latib A, Ho E, Goldberg Y, Shah P, Nyman C, Rodés-Cabau J, Bédard E, Brugger N, Sannino A, Mack MJ, Leon MB, Windecker S. Transfemoral tricuspid valve replacement and one-year outcomes: the TRISCEND study. *Eur Heart J.* 2023;44:4862-73.
56. Hohmann C, Ludwig M, Walker J, Iliadis C, Schipper JH, Baldus S, Pfister R. Real-world anticoagulatory treatment after percutaneous mitral

- valve repair using MitraClip: a retrospective, observational study on 1300 patients. *Clin Res Cardiol*. 2022;111:889-99.
57. Vincent F, Redfors B, Kotinkaduwa LN, Kar S, Lim DS, Mishell JM, Whisenant BK, Lindenfeld J, Abraham WT, Mack MJ, Stone GW. Cerebrovascular Events After Transcatheter Edge-to-Edge Repair and Guideline-Directed Medical Therapy in the COAPT Trial. *JACC Cardiovasc Interv*. 2023;16:1448-59.
  58. El Bèze N, Himbert D, Suc G, Brochet E, Ajzenberg N, Cailliau A, Kikoïne J, Delhomme C, Carrasco JL, Ou P, Iung B, Urena M. Comparison of Direct Oral Anticoagulants vs Vitamin K Antagonists After Transcatheter Mitral Valve Replacement. *J Am Coll Cardiol*. 2024;83:334-46.
  59. Nathan AS, Yang L, Geng Z, Dayoub EJ, Khatana SAM, Fiorilli PN, Herrmann HC, Szeto WY, Atluri P, Acker MA, Desai ND, Frankel DS, Marchlinski FE, Fanaroff AC, Giri J, Groeneveld PW. Oral anticoagulant use in patients with atrial fibrillation and mitral valve repair. *Am Heart J*. 2021;232:1-9.
  60. Mentias A, Saad M, Michael M, Nakhla S, Menon V, Harb S, Chaudhury P, Johnston D, Saliba W, Wazni O, Svensson L, Desai MY, Kapadia S. Direct Oral Anticoagulants Versus Warfarin in Patients With Atrial Fibrillation and Valve Replacement or Repair. *J Am Heart Assoc*. 2022;11:e026666.
  61. Pristipino C, Sievert H, D'Ascenzo F, Mas JL, Meier B, Scacciarella P, Hildick-Smith D, Gaita F, Toni D, Kyrle P, Thomson J, Derumeaux G, Onorato E, Sibbing D, Germonpré P, Berti S, Chessa M, Bedogni F, Dudek D, Hornung M, Zamorano J; European Association of Percutaneous Cardiovascular Interventions (EAPCI); European Stroke Organisation (ESO); European Heart Rhythm Association (EHRA); European Association for Cardiovascular Imaging (EACVI); Association for European Paediatric and Congenital Cardiology (AEPC); ESC Working group on GUCH; ESC Working group on Thrombosis; European Haematological Society (EHA). European position paper on the management of patients with patent foramen ovale. General approach and left circulation thromboembolism. *EuroIntervention*. 2019;14:1389-402.
  62. Kavinsky CJ, Szerlip M, Goldsweig AM, Amin Z, Boudoulas KD, Carroll JD, Coylewright M, Elmariyah S, MacDonald LA, Shah AP, Spies C, Tobis JM, Messé SR, Senerth E, Falck-Ytter Y, Babatunde I, Morgan RL. SCAI Guidelines for the Management of Patent Foramen Ovale. *J Soc Cardiovasc Angiogr Interv*. 2022;1:100039.
  63. Jalal Z, Seguela PE, Baruteau AE, Benoist D, Bernus O, Villemain O, Boudjemline Y, Iriart X, Thambo JB. Role of animal models for percutaneous atrial septal defect closure. *J Thorac Dis*. 2018;10(Suppl 24):S2966-74.
  64. Apostolos A, Drakopoulou M, Gregoriou S, Synetos A, Trantalis G, Tsigvoulis G, Deftereos S, Tsioufis K, Toutouzias K. Nickel Hypersensitivity to Atrial Septal Occluders: Smoke Without Fire? *Clin Rev Allergy Immunol*. 2022;62:476-83.
  65. Krumsdorf U, Ostermayer S, Billinger K, Trepels T, Zadan E, Horvath K, Sievert H. Incidence and clinical course of thrombus formation on atrial septal defect and patent foramen ovale closure devices in 1,000 consecutive patients. *J Am Coll Cardiol*. 2004;43:302-9.
  66. Guedeny P, Farjat-Pasos JJ, Asslo G, Roule V, Beygui F, Hermida A, Gabrion P, Leborgne L, Houde C, Huang F, Lattuca B, Leclercq F, Mesnier J, Abtan J, Rouanet S, Hammoudi N, Collet JP, Zeitouni M, Silvain J, Montalescot G, Rodés-Cabau J; AIR-FORCE Task Force. Impact of the antiplatelet strategy following patent foramen ovale percutaneous closure. *Eur Heart J Cardiovasc Pharmacother*. 2023;9:601-7.
  67. Rodés-Cabau J, Horlick E, Ibrahim R, Cheema AN, Labinaz M, Nadeem N, Osten M, Côté M, Marsal JR, Rivest D, Marrero A, Houde C. Effect of Clopidogrel and Aspirin vs Aspirin Alone on Migraine Headaches After Transcatheter Atrial Septal Defect Closure: The CANOA Randomized Clinical Trial. *JAMA*. 2015;314:2147-54.
  68. Deng W, Yin S, McMullin D, Inglessis-Azuaje I, Elmariyah S, Hung J, Lo EH, Palacios IF, Buonanno FS, Ning M. Residual Shunt After Patent Foramen Ovale Closure and Long-Term Stroke Recurrence: A Prospective Cohort Study. *Ann Intern Med*. 2020;172:717-25.
  69. Alperi A, Guedeny P, Horlick E, Nombela-Franco L, Freixa X, Pascual I, Mesnier J, Houde C, Abrahamyan L, Montalescot G, Rodés-Cabau J. Transcatheter Closure of Patent Foramen Ovale in Older Patients With Cryptogenic Thromboembolic Events. *Circ Cardiovasc Interv*. 2022;15:e011652.
  70. Farjat-Pasos JJ, Guedeny P, Houde C, Alperi A, Robichaud M, Côté M, Montalescot G, Rodés-Cabau J. Sex Differences in Patients With Cryptogenic Cerebrovascular Events Undergoing Transcatheter Closure of Patent Foramen Ovale. *J Am Heart Assoc*. 2023;12:e030359.
  71. Wintzer-Wehekind J, Alperi A, Houde C, Côté JM, Guimaraes LFC, Côté M, Rodés-Cabau J. Impact of Discontinuation of Antithrombotic Therapy Following Closure of Patent Foramen Ovale in Patients With Cryptogenic Embolism. *Am J Cardiol*. 2019;123:1538-45.
  72. Rigatelli G, Zuin M, Dell'Avvocata F, Roncon L, Vassilev D, Nghia N. Light anti-thrombotic regimen for prevention of device thrombosis and/or thrombotic complications after interatrial shunts device-based closure. *Eur J Intern Med*. 2020;74:42-8.
  73. Khan F, Derbas LA, Messé SR, Kavinsky C, Kasner SE, Favilla CG. Management of Patients With Patent Foramen Ovale and Stroke: A National Survey of Interventional Cardiologists and Vascular Neurologists. *J Am Heart Assoc*. 2023;12:e029451.
  74. Hindricks G, Potpara T, Dagres N, Arbelo E, Bax JJ, Blomström-Lundqvist C, Boriani G, Castella M, Dan GA, Dilaveris PE, Fauchier L, Filippatos G, Kalman JM, La Meir M, Lane DA, Lebeau JP, Letiche M, Lip GYH, Pinto FJ, Thomas GN, Valgimigli M, Van Gelder IC, Van Putte BP, Watkins CL; ESC Scientific Document Group. 2020 ESC Guidelines for the diagnosis and management of atrial fibrillation developed in collaboration with the European Association for Cardio-Thoracic Surgery (EACTS): The Task Force for the diagnosis and management of atrial fibrillation of the European Society of Cardiology (ESC) Developed with the special contribution of the European Heart Rhythm Association (EHRA) of the ESC. *Eur Heart J*. 2021;42:373-498.
  75. Freeman JV, Higgins AY, Wang Y, Du C, Friedman DJ, Daimee UA, Minges KE, Pereira L, Goldsweig AM, Price MJ, Reddy VY, Gibson D, Doshi SK, Varosy PD, Masoudi FA, Curtis JP. Antithrombotic Therapy After Left Atrial Appendage Occlusion in Patients With Atrial Fibrillation. *J Am Coll Cardiol*. 2022;79:1785-98.
  76. Glikson M, Wolff R, Hindricks G, Mandrolia J, Camm AJ, Lip GYH, Fauchier L, Betts TR, Lewalter T, Saw J, Tzikas A, Sternik L, Nietlispach F, Berti S, Sievert H, Bertog S, Meier B. EHRA/EAPCI expert consensus statement on catheter-based left atrial appendage occlusion - an update. *EuroIntervention*. 2020;15:1133-80.
  77. Alkhouli M, Busu T, Shah K, Osman M, Alqahtani F, Raybuck B. Incidence and Clinical Impact of Device-Related Thrombus Following Percutaneous Left Atrial Appendage Occlusion: A Meta-Analysis. *JACC Clin Electrophysiol*. 2018;4:1629-37.
  78. Fauchier L, Cinaud A, Brigadeau F, Lepillier A, Pierre B, Abbey S, Fatemi M, Franceschi F, Guedeny P, Jacon P, Paziand O, Venier S, Deharo JC, Gras D, Klug D, Mansourati J, Montalescot G, Piot O, Defaye P. Device-Related Thrombosis After Percutaneous Left Atrial Appendage Occlusion for Atrial Fibrillation. *J Am Coll Cardiol*. 2018;71:1528-36.
  79. Alkhouli M, Alarouri H, Kramer A, Korsholm K, Collins J, De Backer O, Hatoum H, Nielsen-Kudsk JE. Device-Related Thrombus After Left Atrial Appendage Occlusion: Clinical Impact, Predictors, Classification, and Management. *JACC Cardiovasc Interv*. 2023;16:2695-707.
  80. Sedaghat A, Vij V, Al-Kassou B, Gloekler S, Galea R, Fürholz M, Meier B, Valgimigli M, O'Hara G, Arzamendi D, Agudelo V, Asmarats L, Freixa X, Flores-Umanzor E, De Backer O, Søndergaard L, Nombela-Franco L, McNerney A, Korsholm K, Nielsen-Kudsk JE, Afzal S, Zeus T, Operhalski F, Schmitz B, Montalescot G, Guedeny P, Iriart X, Miton N, Saw J, Gilhofer T, Fauchier L, Veliqi E, Meincke F, Petri N, Nordbeck P, Ryczer S, Ognerubov D, Merkulov E, Cruz-González I, Gonzalez-Ferreiro R, Bhatt DL, Laricchia A, Mangieri A, Omran H, Schrickel JW, Rodes-Cabau J, Nickenig G. Device-Related Thrombus After Left Atrial Appendage Closure: Data on Thrombus Characteristics, Treatment Strategies, and Clinical Outcomes From the EUROCD-DRF-Registry. *Circ Cardiovasc Interv*. 2021;14:e010195.
  81. Simard T, Jung RG, Lehenbauer K, Piayda K, Pracoñ R, Jackson GG, Flores-Umanzor E, Faroux L, Korsholm K, Chun JKR, Chen S, Maarse M, Montrella K, Chaker Z, Spoon JN, Pastormerlo LE, Meincke F, Sawant AC, Moldovan CM, Qintar M, Aktas MK, Branca L, Radinovic A, Ram P, El-Zein RS, Flautt T, Ding WY, Sayegh B, Benito-González T, Lee OH, Badejoko SO, Paitazoglou C, Karim N, Zaghoul AM, Agrawal H, Kaplan RM, Alli O, Ahmed A, Suradi HS, Knight BP, Alla VM, Panaich SS,

- Wong T, Bergmann MW, Chothia R, Kim JS, Pérez de Prado A, Bazaz R, Gupta D, Valderrabano M, Sanchez CE, El Chami MF, Mazzone P, Adamo M, Ling F, Wang DD, O'Neill W, Wojakowski W, Pershad A, Berti S, Spoon D, Kawsara A, Jabbour G, Boersma LVA, Schmidt B, Nielsen-Kudsk JE, Rodés-Cabau J, Freixa X, Ellis CR, Fauchier L, Demkow M, Sievert H, Main ML, Hibbert B, Holmes DR Jr, Alkhouli M. Predictors of Device-Related Thrombus Following Percutaneous Left Atrial Appendage Occlusion. *J Am Coll Cardiol*. 2021;78:297-313.
82. Nielsen-Kudsk JE. Prevention of Left Atrial Appendage Device-Related Thrombosis: Is Reduced-Dose Direct Oral Anticoagulation the Way Forward? *JACC Cardiovasc Interv*. 2021;14:2365-7.
83. Lakkireddy D, Thaler D, Ellis CR, Swarup V, Sondergaard L, Carroll J, Gold MR, Hermiller J, Diener HC, Schmidt B, MacDonald L, Mansour M, Maini B, O'Brien L, Windecker S. Amplatzer Amulet Left Atrial Appendage Occluder Versus Watchman Device for Stroke Prophylaxis (Amulet IDE): A Randomized, Controlled Trial. *Circulation*. 2021;144:1543-52.
84. Galea R, De Marco F, Meneveau N, Aminian A, Anselme F, Gräni C, Huber AT, Teiger E, Iriart X, Babongo Bosombo F, Heg D, Franzone A, Vranckx P, Fischer U, Pedrazzini G, Bedogni F, Räber L, Valgimigli M. Amulet or Watchman Device for Percutaneous Left Atrial Appendage Closure: Primary Results of the SWISS-APER0 Randomized Clinical Trial. *Circulation*. 2022;145:724-38.
85. Galea R, Meneveau N, De Marco F, Aminian A, Heg D, Chalkou K, Gräni C, Anselme F, Franzone A, Vranckx P, Fischer U, Bedogni F, Räber L, Valgimigli M. One-Year Outcomes After Amulet or Watchman Device for Percutaneous Left Atrial Appendage Closure: A Prespecified Analysis of the SWISS-APER0 Randomized Clinical Trial. *Circulation*. 2024;149:484-6.
86. Carvalho PEP, Gewehr DM, Miyawaki IA, Nogueira A, Felix N, Garot P, Darmon A, Mazzone P, Preda A, Nascimento BR, Kubrusly LF, Cardoso R. Network Meta-Analysis of Initial Antithrombotic Regimens After Left Atrial Appendage Occlusion. *J Am Coll Cardiol*. 2023;82:1765-73.
87. Della Rocca DG, Magnocavallo M, Di Biase L, Mohanty S, Trivedi C, Tarantino N, Gianni C, Lavalle C, Van Niekerk CJ, Romero J, Briceño DF, Bassiouny M, Al-Ahmad A, Burkhardt JD, Natale VN, Gallinhouse GJ, Del Prete A, Forleo GB, Sanchez J, Lakkireddy D, Horton RP, Gibson DN, Natale A. Half-Dose Direct Oral Anticoagulation Versus Standard Antithrombotic Therapy After Left Atrial Appendage Occlusion. *JACC Cardiovasc Interv*. 2021;14:2353-64.
88. Duthoit G, Silvain J, Marijon E, Ducrocq G, Lepillier A, Frere C, Dimby SF, Popovic B, Lellouche N, Martin-Toutain I, Spaulding C, Brochet E, Attias D, Mansourati J, Lorgis L, Klug D, Zannad N, Hauguel-Moreau M, Braik N, Deltour S, Ceccaldi A, Wang H, Hammoudi N, Brugier D, Vicaut E, Juliard JM, Montalescot G. Reduced Rivaroxaban Dose Versus Dual Antiplatelet Therapy After Left Atrial Appendage Closure: ADRIFT a Randomized Pilot Study. *Circ Cardiovasc Interv*. 2020;13:e008481.
89. Freixa X, et al. Low dose direct oral anticoagulation vs. DAPT after LAAO – ADALA Trial. Presented at: EuroPCR 2023; 17 May 2023; Paris, France.
90. Alaour B, Ferrari E, Heg D, Tueller D, Pilgrim T, Muller O, Noble S, Jeger R, Reuthebuch O, Toggweiler S, Templin C, Wenaweser P, Nietlispach F, Taramasso M, Huber C, Roffi M, Windecker S, Stortecky S. Non-Vitamin K Antagonist Versus Vitamin K Antagonist Oral Anticoagulant Agents After Transcatheter Aortic Valve Replacement. *JACC Cardiovasc Interv*. 2024;17:405-18.
91. Hohmann C, Pfister R, Frerker C, Beckmann A, Walther T, Bleiziffer S, Ensminger S, Bekeredjian R, Seiffert M, Sinning JM, Möllmann H, Beyersdorf F, Baldus S, Böning A, Herrmann E, Balaban Ü, Kuhn E; GARY Executive Board. Direct oral anticoagulants versus vitamin K antagonist after transcatheter aortic valve implantation. *Heart*. 2023;109:1706-13.
92. Butt JH, De Backer O, Olesen JB, Gerds TA, Havers-Borgersen E, Gislason GH, Torp-Pedersen C, Søndergaard L, Køber L, Fosbøl EL. Vitamin K antagonists vs. direct oral anticoagulants after transcatheter aortic valve implantation in atrial fibrillation. *Eur Heart J Cardiovasc Pharmacother*. 2021;7:11-9.
93. Didier R, Lhermusier T, Auffret V, Eltchaninoff H, Le Breton H, Cayla G, Commeau P, Collet JP, Cuisset T, Dumonteil N, Verhoye JP, Beurtheret S, Lefèvre T, Teiger E, Carrié D, Himbert D, Albat B, Cribier A, Sudre A, Blanchard D, Bar O, Rioufol G, Collet F, Houel R, Labrousse L, Meneveau N, Ghostine S, Manigold T, Guyon P, Delepine S, Favereau X, Souteyrand G, Ohlmann P, Doisy V, Beygui F, Gommeaux A, Claudel JP, Bourlon F, Bertrand B, Iung B, Gilard M; STOP-AS and France-TAVI. TAVR Patients Requiring Anticoagulation: Direct Oral Anticoagulant or Vitamin K Antagonist? *JACC Cardiovasc Interv*. 2021;14:1704-13.
94. Kawashima H, Watanabe Y, Hioki H, Kozuma K, Kataoka A, Nakashima M, Nagura F, Nara Y, Yashima F, Tada N, Naganuma T, Yamawaki M, Yamanaka F, Shirai S, Mizutani K, Tabata M, Ueno H, Takagi K, Yamamoto M, Hayashida K; OCEAN-TAVI Investigator. Direct Oral Anticoagulants Versus Vitamin K Antagonists in Patients With Atrial Fibrillation After TAVR. *JACC Cardiovasc Interv*. 2020;13:2587-97.
95. Jochheim D, Barbanti M, Capretti G, Stefanini GG, Hapfelmeier A, Zadrozny M, Baquet M, Fischer J, Theiss H, Todaro D, Chieffo A, Presbitero P, Colombo A, Massberg S, Tamburino C, Mehilli J. Oral Anticoagulant Type and Outcomes After Transcatheter Aortic Valve Replacement. *JACC Cardiovasc Interv*. 2019;12:1566-76.